

# ICAR CLAW HEALTH ATLAS



# Publishing Information

**Title of the Series:** ICAR Technical Series

**Title of the Issue:** ICAR Claw Health Atlas

**Editors:** ICAR Working Group on Functional Traits (ICAR WGFT) and International Claw Health Experts (see page 6-7)

**Coordination of work:** Christa Egger-Danner

**Responsible for harmonized descriptions / Citation of the ICAR Claw Health Atlas:**

Egger-Danner, C., Nielsen, P., Fiedler, A., Müller, K., Fjeldaas, T., Döpfer, D., Daniel, V., Bergsten, C., Cramer, G., Christen, A.-M., Stock, K. F., Thomas, G., Holzhauer, M., Steiner, A., Clarke, J., Capion, N., Charfeddine, N., Pryce, E., Oakes, E., Burgstaller, J., Heringstad, B., Ødegård, C. and J. Kofler

[http://www.icar.org/Documents/ICAR\\_Claw\\_Health\\_Atlas.pdf](http://www.icar.org/Documents/ICAR_Claw_Health_Atlas.pdf)

**Layout and design:** Franziska Egger, Hollenstein, Austria

**Editing of text and pictures:** John Cole, USA and Johann Kofler, Austria

**Publisher:** ICAR, Via Savoia 78, Scala A, Int. 3, 00191, Rome, Italy; Tel: +39 06 85 237 1; Email: [icar@icar.org](mailto:icar@icar.org)

**Copyright by:** ICAR, Via Savoia 78, Scala A, Int. 3, 00191, Rome, Italy

**ISSN:** 92-95014-14-6

**ISBN:** 92-95014-18

**Edition:** First edition, June 2015

# Table of Contents

|                                     |    |
|-------------------------------------|----|
| Foreword                            | 4  |
| Introduction                        | 5  |
| Authors and Contributors            | 6  |
| Overview of Foot and Claw Disorders | 9  |
| List of Pictures                    | 44 |



© Pesenhofer, AUT



# Foreword

ICAR is an international organisation with the mission of promoting the development and improvement of performance recording and genetic evaluation of farm livestock. Our members are animal recording organisations from around the world and associates who provide services to the animal recording industry. Our eighteen technical Groups, each of which focuses on specific aspects of animal recording or genetic evaluation, carry out much of our work. The work of our Groups generally covers: standards & guidelines, communications, surveys, and innovation. Their output is available from the ICAR website (<http://www.icar.org/>) and is reported at the annual ICAR meetings. ICAR is particularly appreciative of the large amount of work undertaken by the experts who provide their time and knowledge, free of charge, to develop international standards and guidelines for animal recording. As a consequence of this work, the information available from ICAR's members around the world is being used to help farmers make decisions leading to a more efficient animal production sector worldwide.

The ICAR Functional Traits Working Group (ICAR WGFT) is particularly active and has focused on a range of very important traits in dairy cattle including: fertility, udder health, and, most recently, feet and legs. This work is part of ICAR's strategy for helping its members to provide better services to farmers and to facilitate the genetic improvement of farmed livestock, particularly dairy cattle. For the first time we now have an international Atlas and coding system for claw traits in dairy cattle. This represents a major step forward in ensuring the incidence of claw defects affecting animal health, welfare, and productivity can be reduced in the future.

ICAR is focused on continuous improvement and welcomes all feedback on how it can improve its services and in particular the quality of its standards and guidelines.

**Hans Wilmink**  
ICAR President



# Introduction

Awareness of the importance of a properly functioning locomotor system to bovine health and welfare has increased around the world. Several countries have recently introduced electronic systems to routinely record foot and claw disorders in dairy cattle and many more countries are developing plans or have committed to begin recording in the near future. This motivated the ICAR working group for functional traits to prioritize foot and claw health and to work with internationally recognized claw experts to develop best practices for data recording. This collaboration is intended to complement existing research on specific aspects of the claws and feet of dairy cattle, focusing solely on the standardization and harmonization of data recording. The harmonized descriptions are the result of fruitful interdisciplinary collaboration among many experts with varying backgrounds (claw health experts, hoof trimmers, bovine practitioners, geneticists), ensuring comprehensive coverage of theoretical and applied needs. It is designed to provide a tool for practitioners and hoof trimmers and presents guidelines for the recording of important conditions affecting the claw health of cattle. Descriptive trait definitions are used to ensure that accurate classifications are made, which will support the collection of comparable and high-quality data within and across countries to support many activities (e.g., genetic evaluation purposes). The authors and contributors to the ICAR Claw Health Atlas hope that the compiled material will support the improved recording of foot and claw disorders and provide a valuable tool for improving the health and welfare of dairy cattle.

## The authors and contributors of the ICAR Claw Health Atlas



© Nielsen, DK



# Authors and Contributors

## **Austria**

Johann Burgstaller, University Clinic for Ruminants,  
University of Veterinary Medicine, Vienna  
Christa Egger-Danner, ZuchtData EDV-Dienstleistungen  
GmbH, Vienna  
Johann Kofler, University Clinic for Ruminants, University  
of Veterinary Medicine, Vienna  
Robert Pesenhofer, Federation of Austrian Hoof Trimmers,  
Hitzendorf

## **Australia**

Jakob Malmo, Maffra Veterinary Centre, Maffra  
Erika Oakes, Dairy Australia, Southbank, Victoria  
Jennie Pryce, Department of Environment and Primary  
Industries and La Trobe University, Agribio, Bundoora, Victoria

## **Belgium**

Nicolas Gengler, Université de Liège - Gembloux Agro-  
Bio Tech, Gembloux

## **Canada**

Anne-Marie Christen, Valacta, Québec  
Victor Daniel, Vic's Custom Clips est. 1984, Quality  
Bovine Hoof Care, Ontario  
Paul R. Greenough, Professor Emeritus of Veterinary  
Surgery, University of Saskatchewan

Filippo Miglior, Canadian Dairy Network and University of  
Guelph, Ontario

Francesca Malchiodi, University of Guelph, Ontario

## **Denmark**

Nynne Capiion, Department of Large Animal Sciences,  
University of Copenhagen, Copenhagen  
Pia Nielsen, SEGES P/S, Aarhus

## **Germany**

Andrea Fiedler, bovine practitioner / Association of  
Certified Hoof Trimmers (VgK e.V.), Munich  
Kerstin Müller, Veterinary Medicine Faculty,  
Freie Universität, Berlin  
Kathrin Friederike Stock, vit - Vereinigte  
Informationssysteme Tierhaltung w.V., Verden

## **Finland**

Reijo Junni, Environmental Health Office of Central  
Ostrobothnia, Kokkola  
Elina Paakala, Faba co-op, Vantaa

## **France**

Joël Blanchard, Hoof trimmers training team at CFPPA,  
Le Rheu  
Marc Delacroix, Veterinarian, member of training team at  
CFPPA, Le Rheu



# Authors and Contributors

Jean Prodhomme, Hoof trimmers training team at CFPPA,  
Le Rheu

Gilles Thomas, Institut de l'Élevage, Paris

## **Ireland**

Keelin O'Driscoll, Teagasc, Moorepark, Cork

## **The Netherlands**

Menno Holzhauser, GD Animal Health, Deventer

Gerben de Jong, CRV, Arnhem

## **New Zealand**

Anna Irwin, DairyNZ, Invercargill

## **Norway**

Terje Fjeldaas, Norwegian University of Life Sciences, Oslo

Björg Heringstad, Norwegian University of Life Sciences /  
Geno, Ås

Cecilie Ødegard, Geno, Ås

Maren Knappe-Poindecker, Norwegian University of Life  
Sciences, Oslo

Åse Margrethe Sogstad, TINE, Ås

## **Spain**

Noureddine Charfeddine, Conafe, Madrid

Adrián González Sagüés, Anka Hoof Care, Orkoien,  
Navarra

Pedro Codesido, Seragro, S. Coop. Galega, A Coruña

## **Switzerland**

Adrian Steiner, University of Bern, Vetsuisse Faculty, Bern

## **Sweden**

Christer Bergsten, Swedish University of Agricultural  
Sciences, Alnarp

Karin Ulvshammar, Växa Sverige, Stockholm

## **United Kingdom**

Andrew J Bradley, Quality Milk Management Services Ltd,  
Somerset

Jonathan Clarke, SKS Foot trimming Services Ltd,  
Seaford, East Sussex

Michael Parkinson, Holstein UK, Herts

Becky Whay, University of Bristol, School of Veterinary  
Sciences Langford, Bristol

## **United States of America**

John Cole, Animal Genomics and Improvement  
Laboratory, ARS, USDA, Beltsville

Dörte Döpfer, Food Animal Production Medicine, School  
of Veterinary Medicine, University of Wisconsin in  
Madison, Madison

Gerard Cramer, College of Veterinary Medicine, University of  
Minnesota, St. Paul





© Daniel, CAN

# Overview of Foot and Claw Disorders

| Name  | Code       | Description  | Synonymous Terms                          | P  |
|---|------------|--|---|----|
| <b>Asymmetric claws</b>                         | <b>AC</b>  | Significant difference in width, height and/or length between outer and inner claw which cannot be balanced by trimming                |   | 12 |
| <b>Concave dorsal wall</b>                      | <b>CD</b>  | Concave shape of the dorsal wall   |   | 13 |
| <b>Corkscrew claws</b>                          | <b>CC</b>  | Any torsion of either the outer or inner claw. The dorsal edge of the wall deviates from a straight line                               |   | 14 |
| <b>Digital dermatitis</b>                       | <b>DD</b>  | Infection of the digital and/or interdigital skin with erosion, mostly painful ulcerations and/or chronic hyperkeratosis/proliferation | Mortellaro disease,<br>Strawberry disease | 15 |
| <b>Interdigital/<br/>superficial dermatitis</b> | <b>ID</b>  | All kind of mild dermatitis around the claws, that is not classified as digital dermatitis   |   | 18 |
| <b>Double sole</b>                              | <b>DS</b>  | Two or more layers of under-run sole horn  | Underrun sole                             | 19 |
| <b>Heel horn erosion</b>                        | <b>HHE</b> | Erosion of the bulbs, in severe cases typically V-shaped, possibly extending to the corium   | Slurry heel,<br>Erosio ungulae            | 21 |
| <b>Horn fissure</b>                             | <b>HF</b>  | Crack in the claw wall   |   |    |
| Axial horn fissure                              | HFA        | Vertical (longitudinal) crack in the inner claw wall   |   | 23 |



# Overview of Foot and Claw Disorders

| Name                               | Code      | Description  | Synonymous Terms   | P  |
|------------------------------------|-----------|--|--|----|
| Horizontal horn fissure            | HFH       | Horizontal crack in the claw wall  |  | 24 |
| Vertical horn fissure              | HFV       | Vertical (longitudinal) crack in the outer or dorsal claw wall   |  | 25 |
| <b>Interdigital hyperplasia</b>    | <b>IH</b> | Interdigital growth of fibrous tissue  | Corns, Tyloma, Interdigital fibroma                      | 26 |
| <b>Interdigital phlegmon</b>       | <b>IP</b> | Symmetric painful swelling of the foot commonly accompanied with odorous smell with sudden onset of lameness | Foot rot, Foul in the foot, Interdigital necrobacillosis | 28 |
| <b>Scissor claws</b>               | <b>SC</b> | Tip of toes crossing each other  |  | 30 |
| <b>Sole hemorrhage</b>             | <b>SH</b> | Diffused and/or circumscribed red or yellow discoloration of the sole and/or white line                      | Sole bruising  |    |
| Sole hemorrhage diffused form      | SHD       | Diffused light red to yellowish discoloration  |  | 31 |
| Sole hemorrhage circumscribed form | SHC       | Clear differentiation between discolored and normal colored horn   |  | 32 |



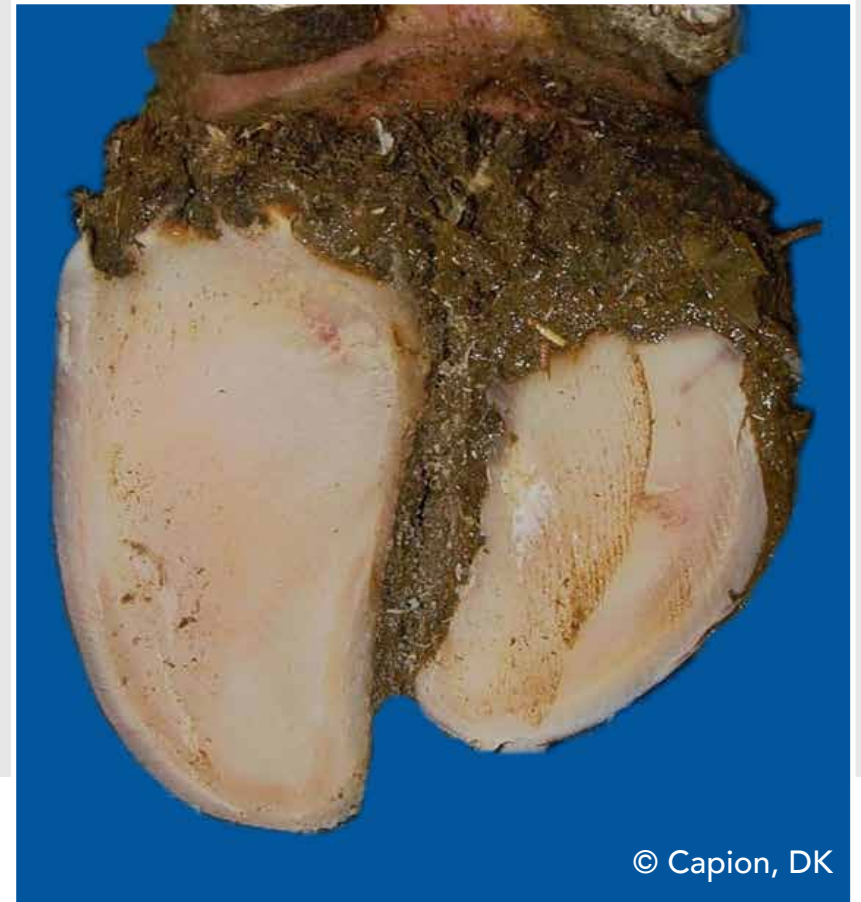
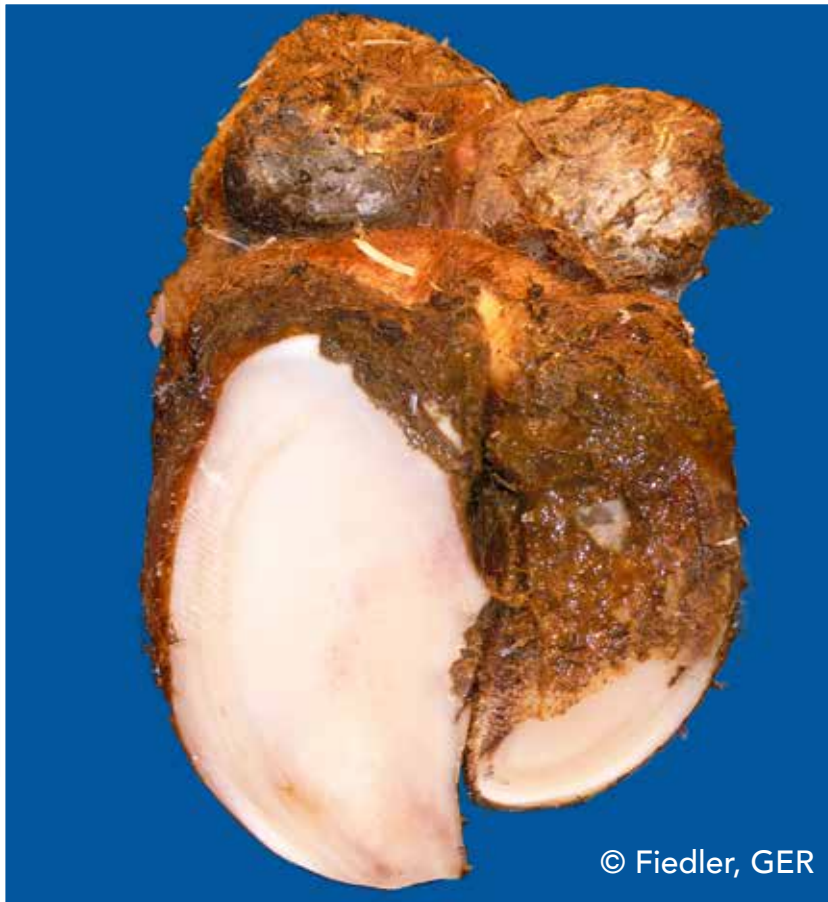# Overview of Foot and Claw Disorders

| Name                                   | Code      | Description   | Synonymous Terms | P  |
|--|-----------|---|------------------|----|
| <b>Swelling of coronet and/or bulb</b> | <b>SW</b> | Uni- or bilateral swelling of tissue above horn capsule, which may be caused by different conditions                            |                  | 33 |
| <b>Ulcer</b>                           | <b>U</b>  | Ulceration of the sole area specified according to localization (zones) such as bulb ulcer, sole ulcer, toe ulcer, toe necrosis |                  |    |
| Sole ulcer                             | SU        | Penetration through the sole horn exposing fresh or necrotic corium   |                  | 35 |
| Bulb ulcer                             | BU        | Ulcer located at the bulb   | Heel ulcer       | 36 |
| Toe ulcer                              | TU        | Ulcer located at the toe  |                  | 37 |
| Toe necrosis                           | TN        | Necrosis of the tip of the toe with involvement of bone tissue  |                  | 38 |
| <b>Thin sole</b>                       | <b>TS</b> | Sole horn yields (feels spongy) when finger pressure is applied   |                  | 40 |
| <b>White line disease</b>              | <b>WL</b> | Separation of the white line with or without purulent exudation   |                  |    |
| White line fissure                     | WLF       | Separation of the white line which remains after balancing both soles   |                  | 41 |
| White line abscess                     | WLA       | Necro-purulent inflammation of the corium   |                  | 42 |



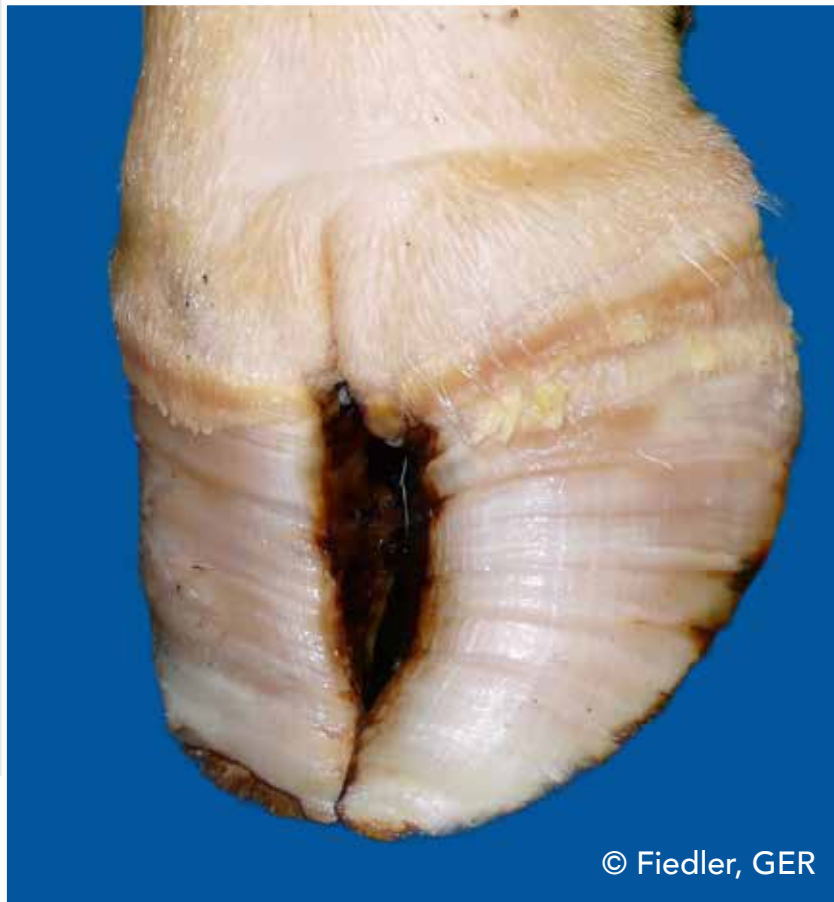# Asymmetric claws (AC)

Significant difference in width, height and/or length between outer and inner claw which cannot be balanced by trimming



# Concave dorsal wall (CD)

Concave shape of the dorsal wall



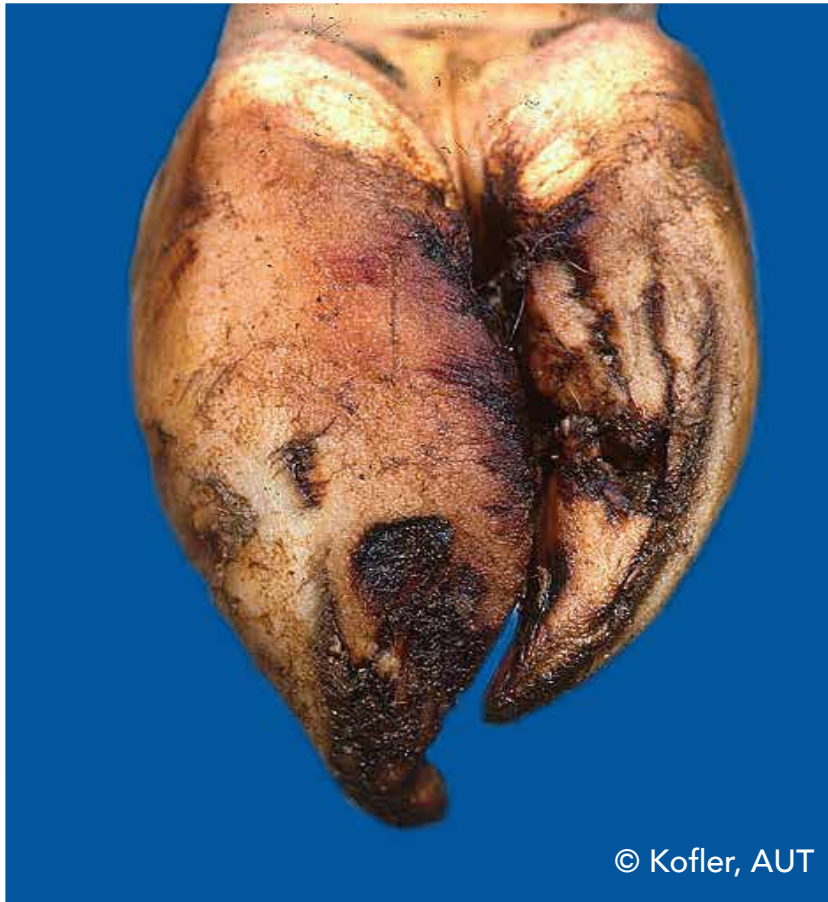© Fiedler, GER



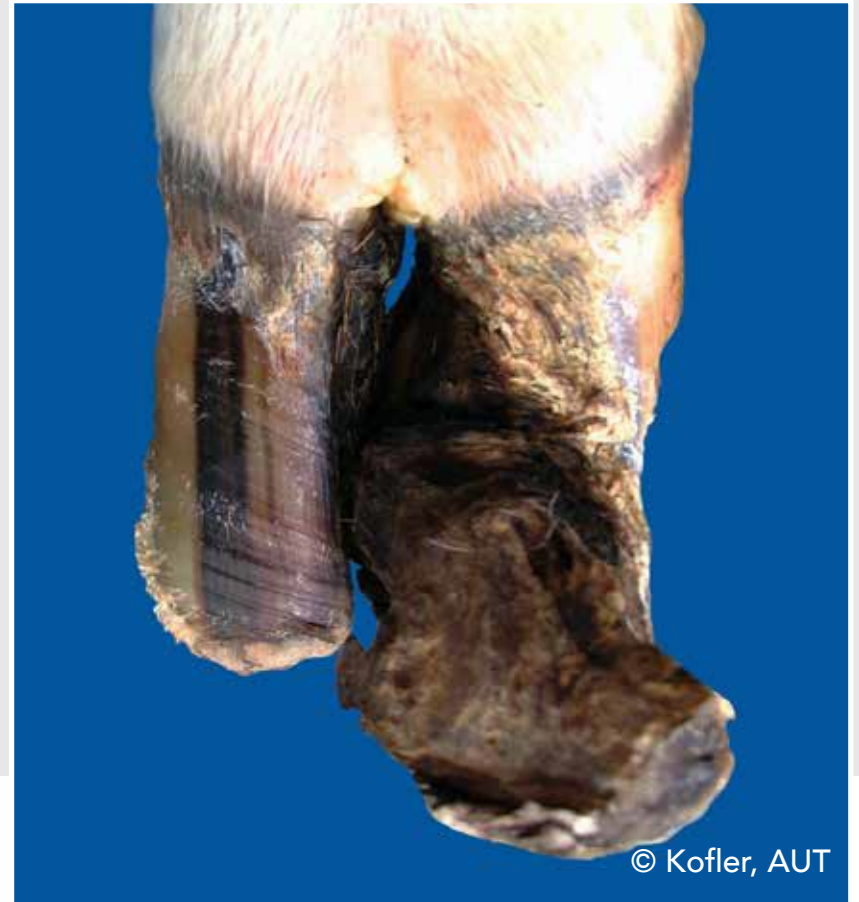© Thomas, FRA

# Corkscrew claw (CC)

Any torsion of either the outer or inner claw. The dorsal edge of the wall deviates from a straight line



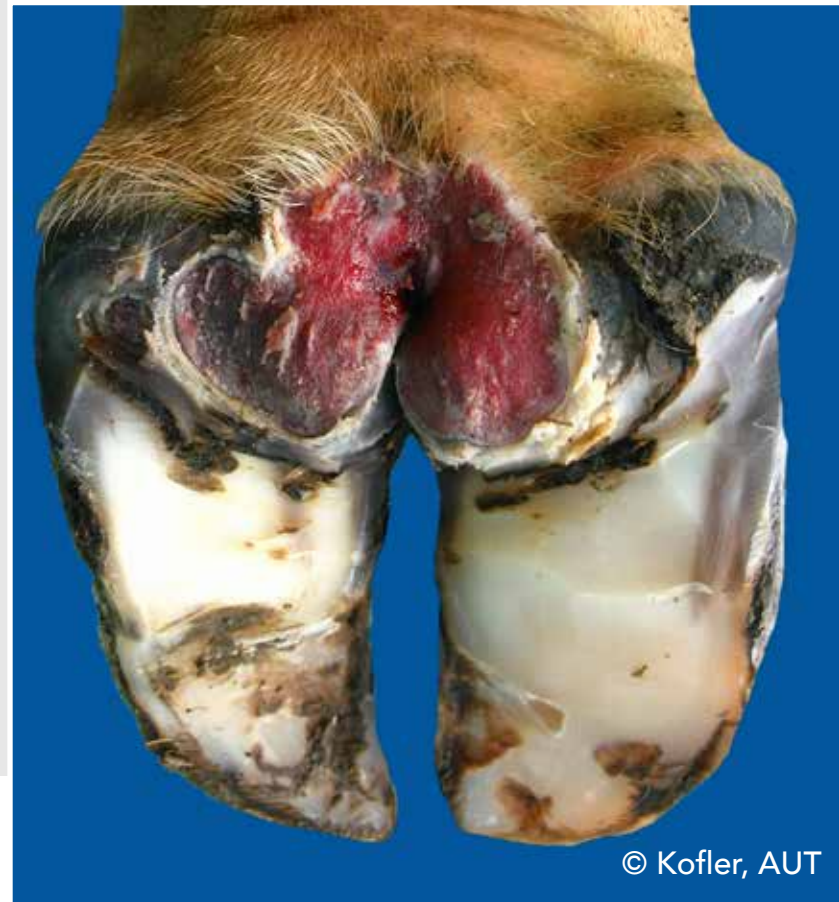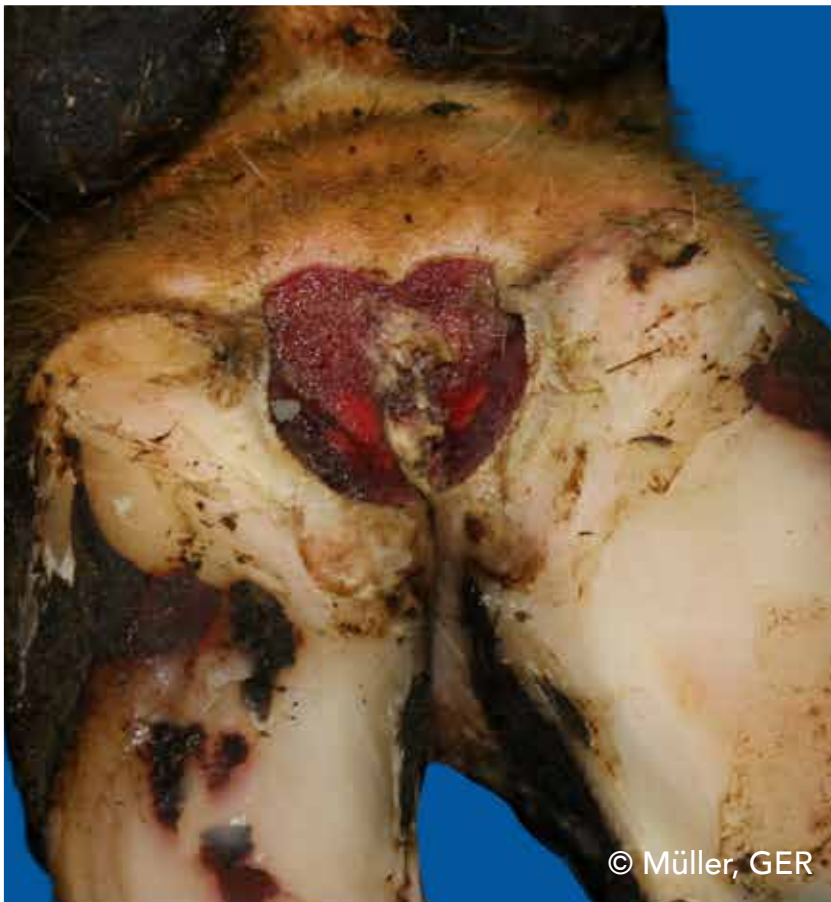© Kofler, AUT



© Kofler, AUT

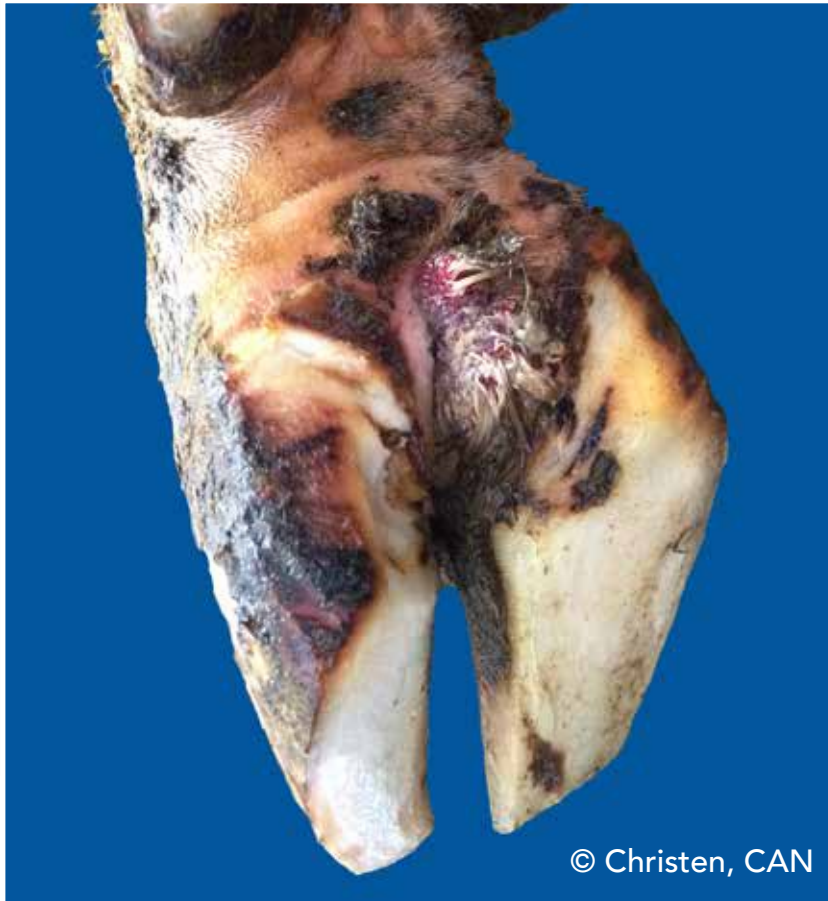# Digital dermatitis (DD)

Infection of the digital and/or interdigital skin with erosion, mostly painful ulcerations and/or chronic hyperkeratosis/proliferation

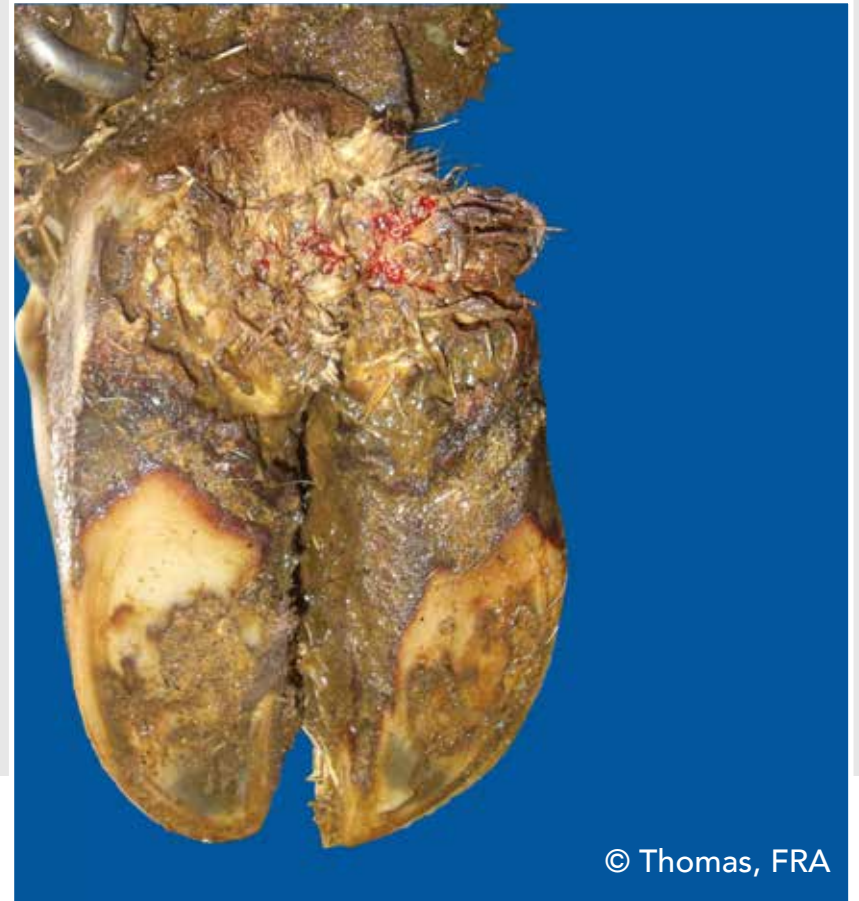

# Digital dermatitis (DD)

Infection of the digital and/or interdigital skin with erosion, mostly painful ulcerations and/or chronic hyperkeratosis/proliferation



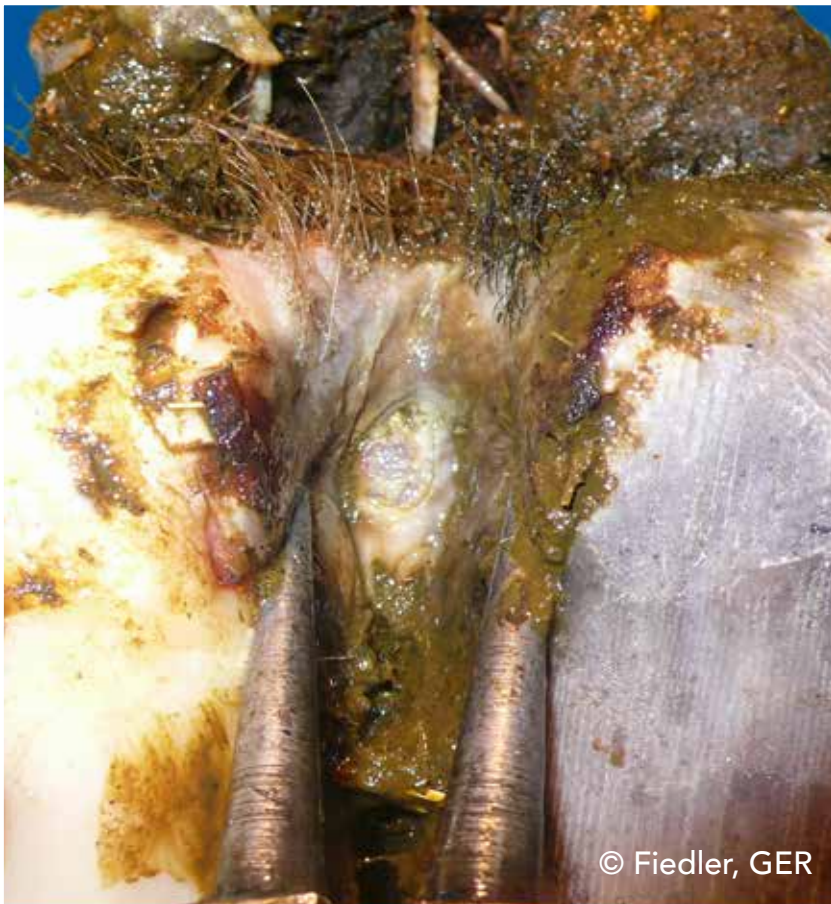© Christen, CAN



© Thomas, FRA

# Digital dermatitis (DD)

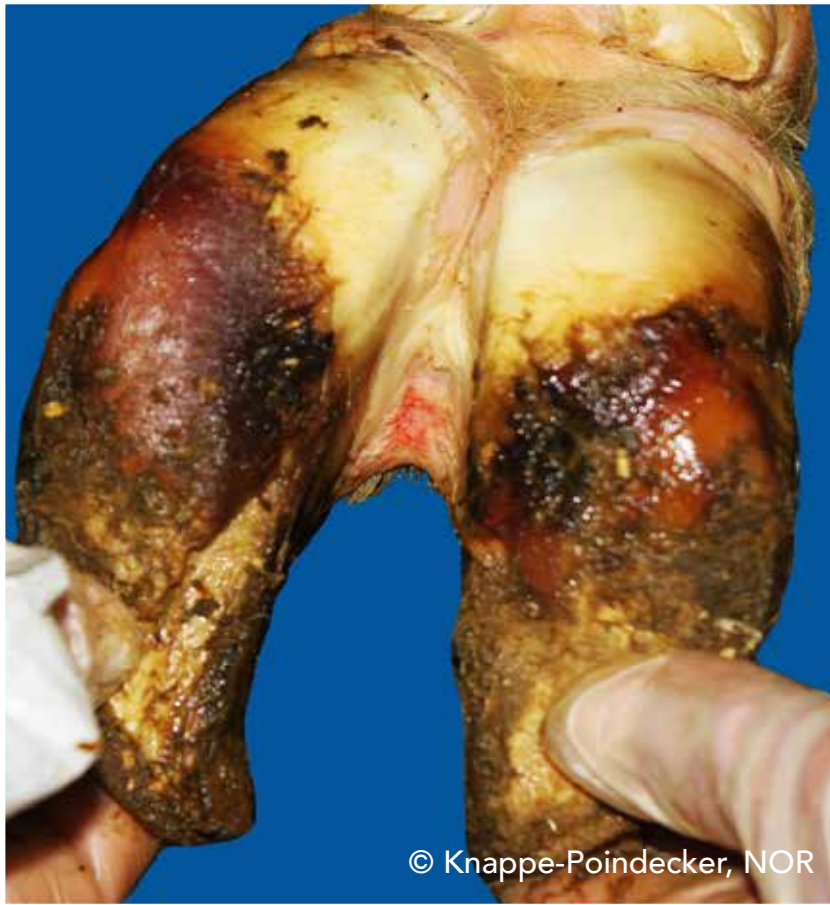Infection of the digital and/or interdigital skin with erosion, mostly painful ulcerations and/or chronic hyperkeratosis/proliferation



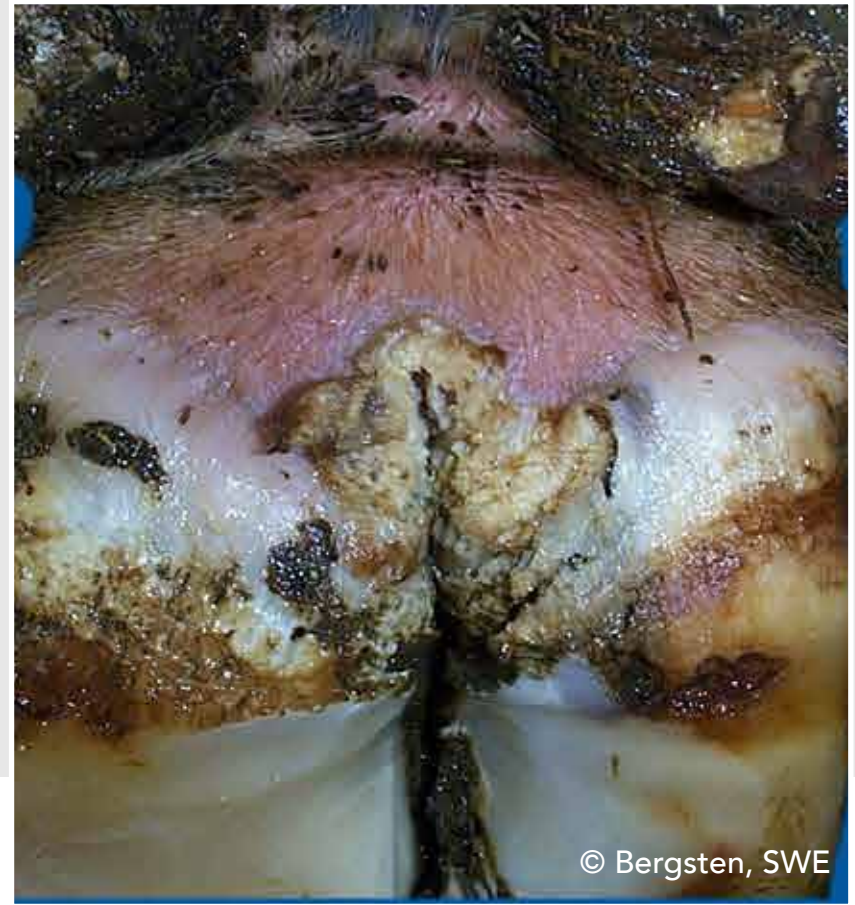
© Fiedler, GER

# Interdigital/superficial dermatitis (ID)

All kind of mild dermatitis around the claws, that is not classified as digital dermatitis



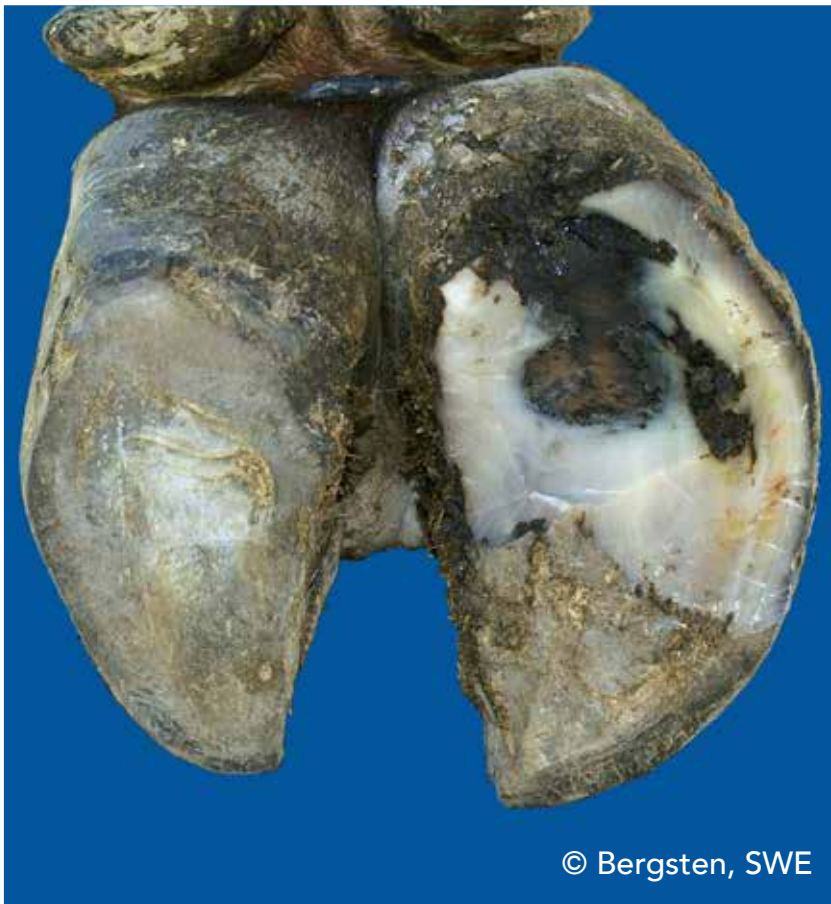© Knappe-Poindecker, NOR



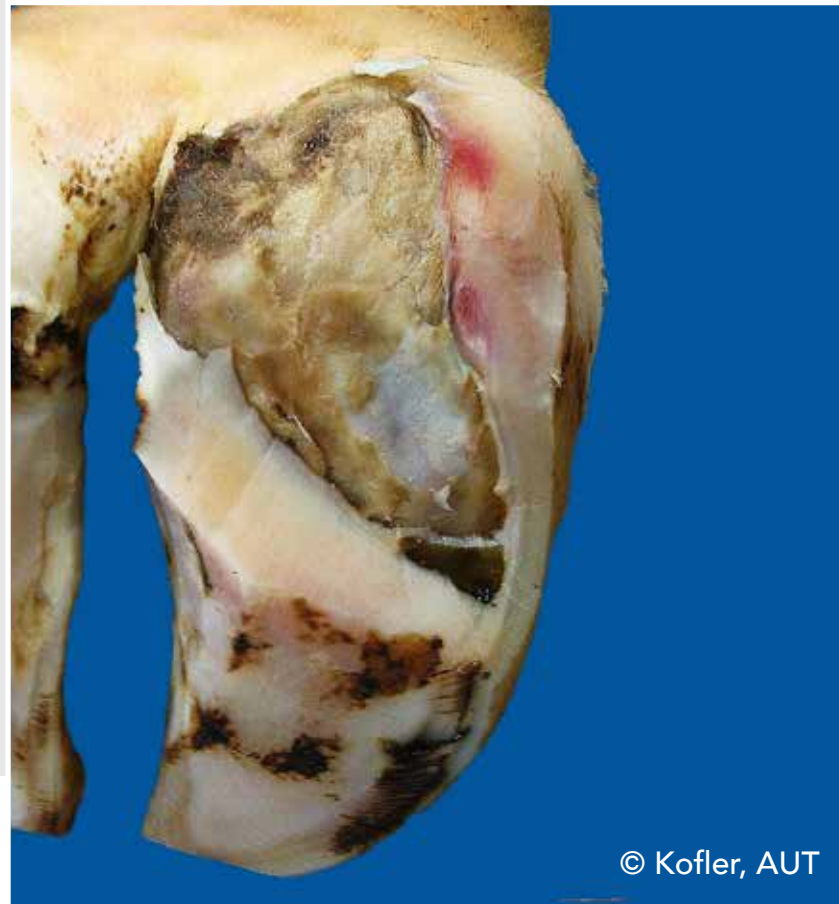© Bergsten, SWE

# Double sole (DS)

Two or more layers of under-run sole horn



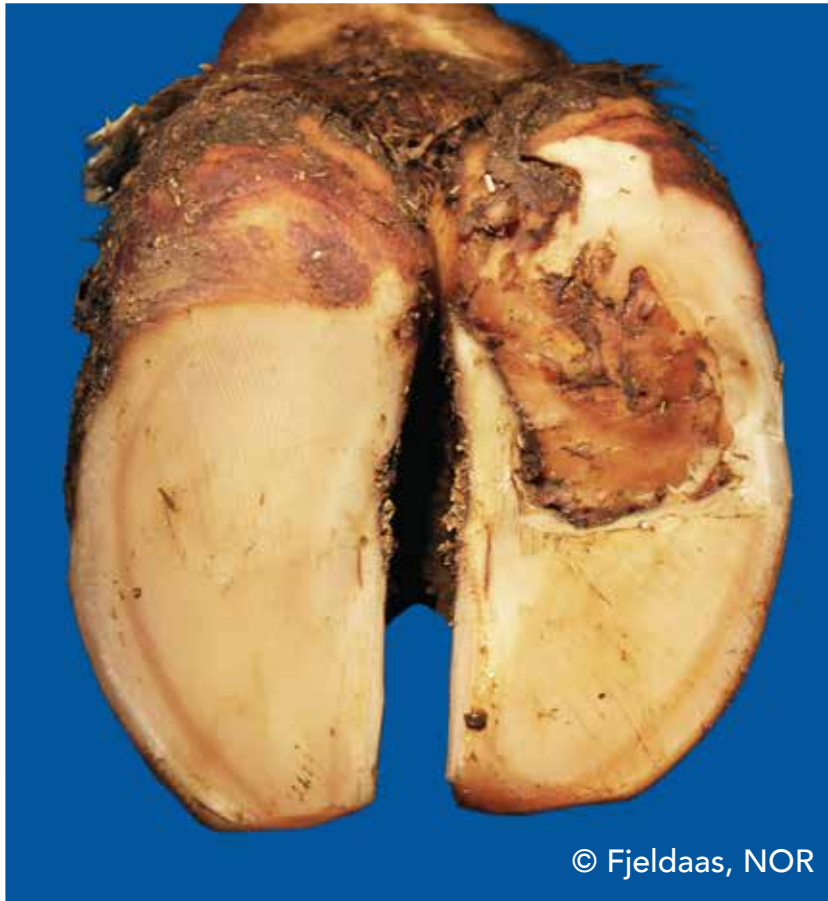© Bergsten, SWE



© Kofler, AUT

# Double sole (DS)

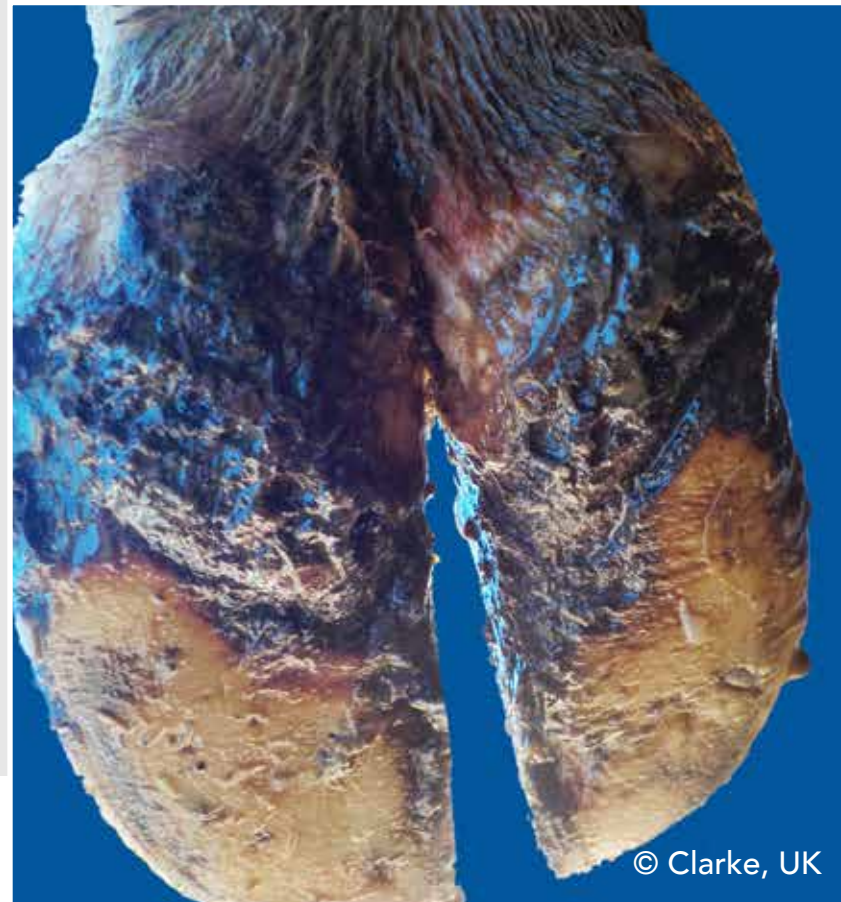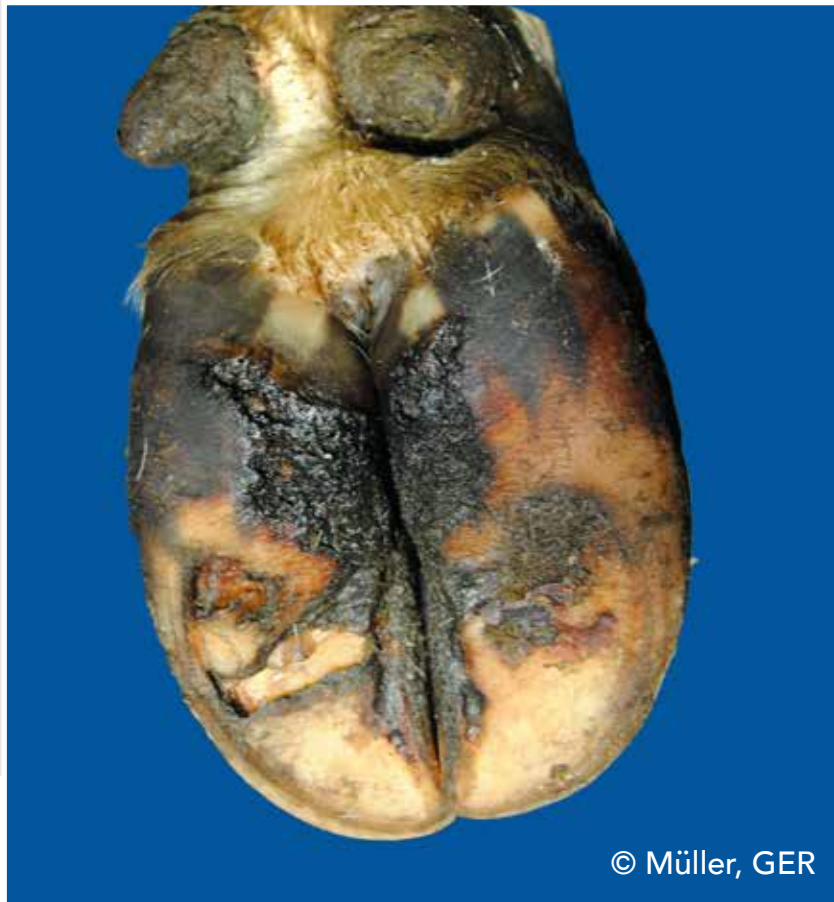Two or more layers of under-run sole horn



© Fjeldaas, NOR

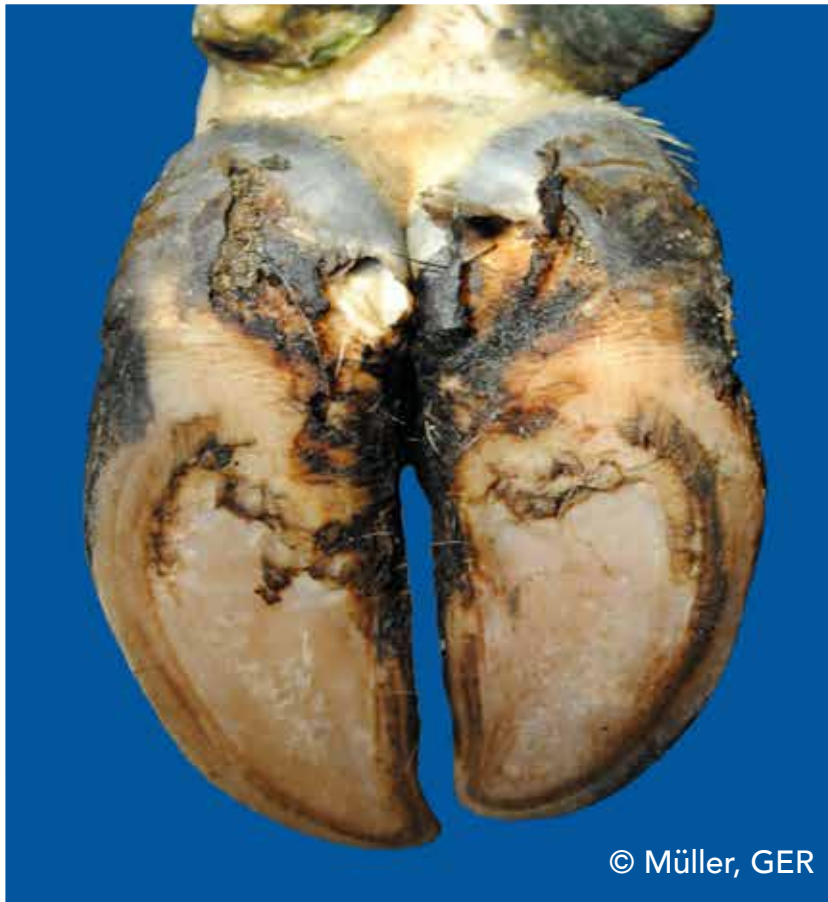
# Heel horn erosion (HHE)

Erosion of the bulbs, in severe cases typically V-shaped, possibly extending to the corium

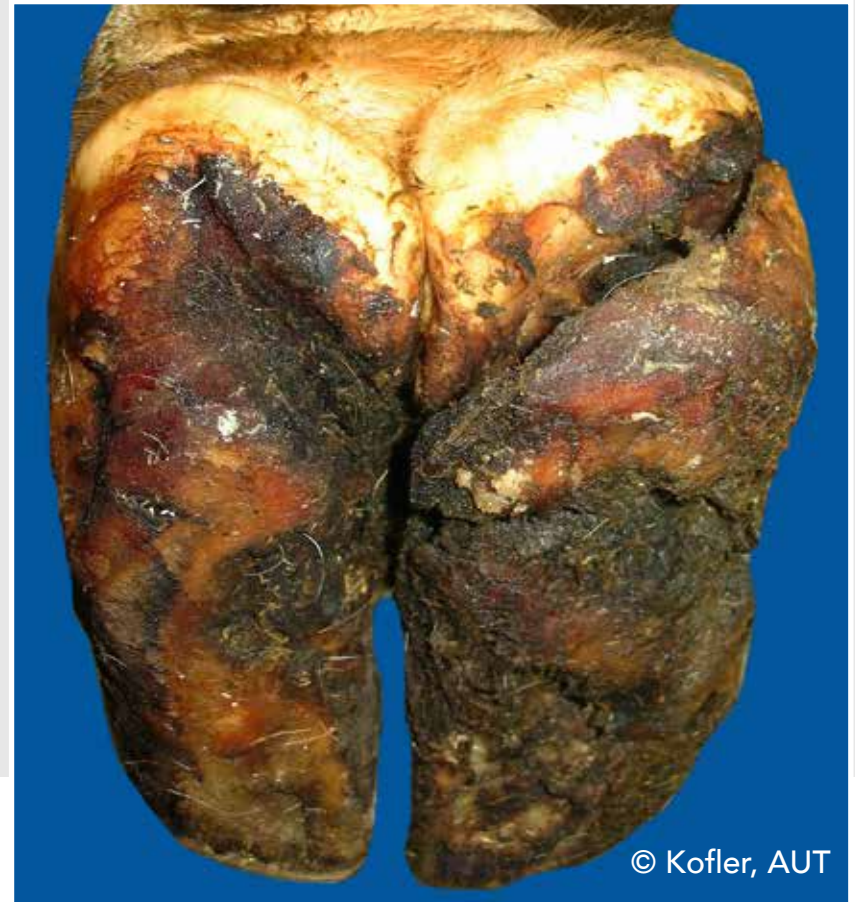

# Heel horn erosion (HHE)

Erosion of the bulbs, in severe cases typically V-shaped, possibly extending to the corium



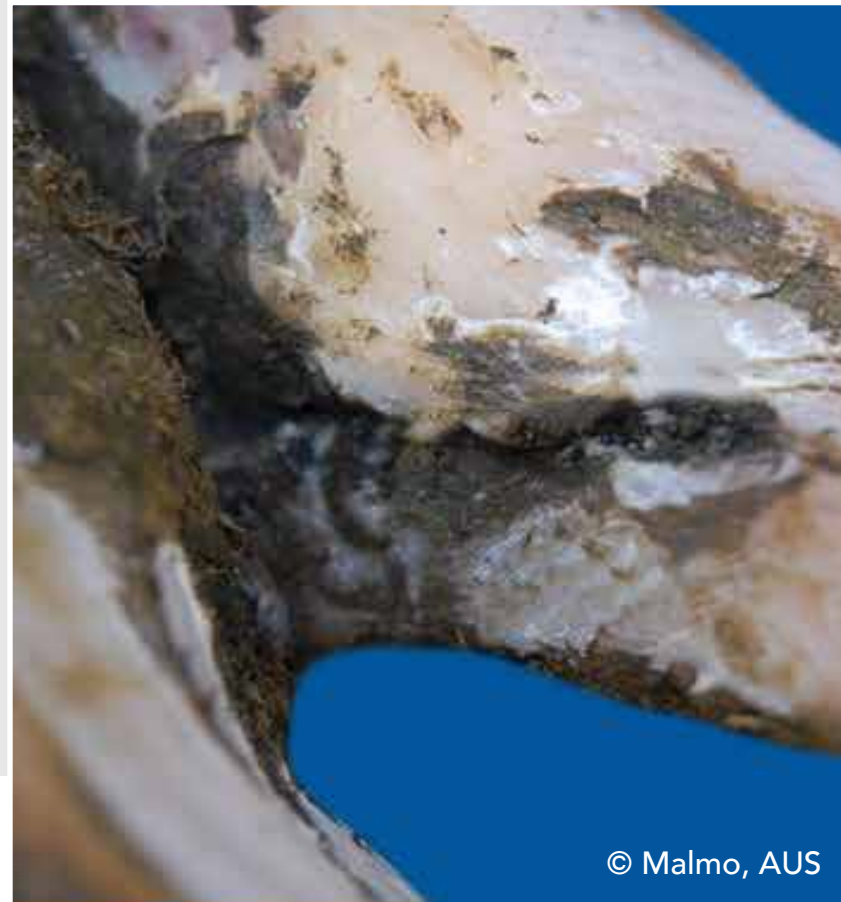
© Müller, GER



© Kofler, AUT

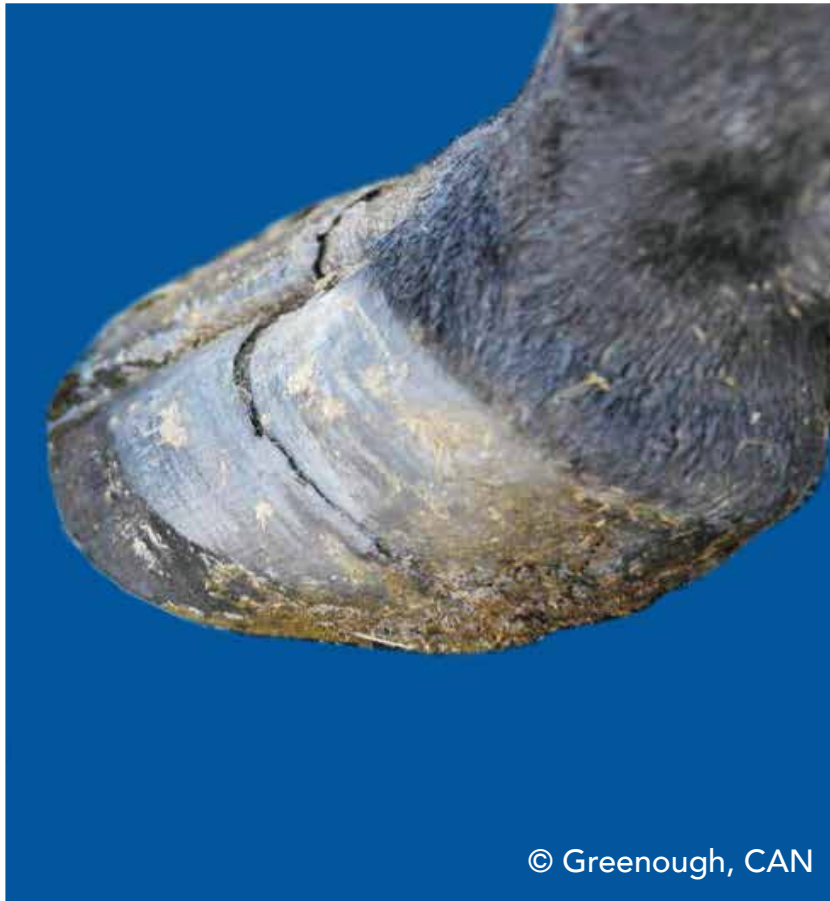
# Axial horn fissure (HFA)

Vertical (longitudinal) crack in the inner claw wall

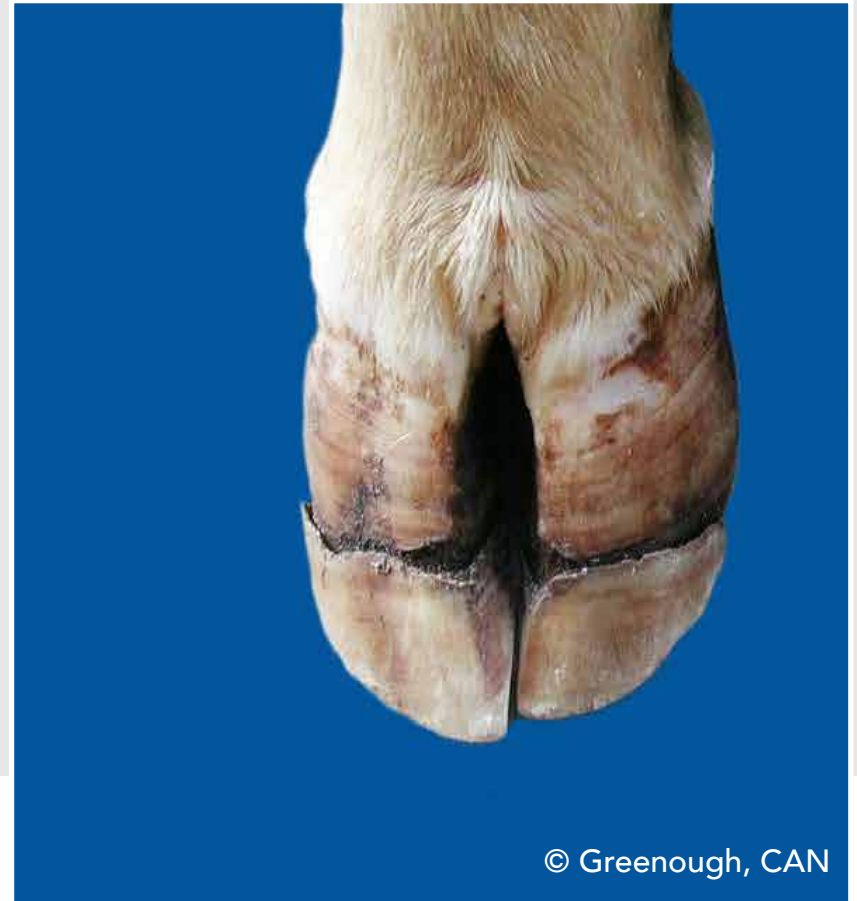

# Horizontal horn fissure (HFH)

Horizontal crack in the claw wall



© Greenough, CAN



© Greenough, CAN

# Vertical horn fissure (HFV)

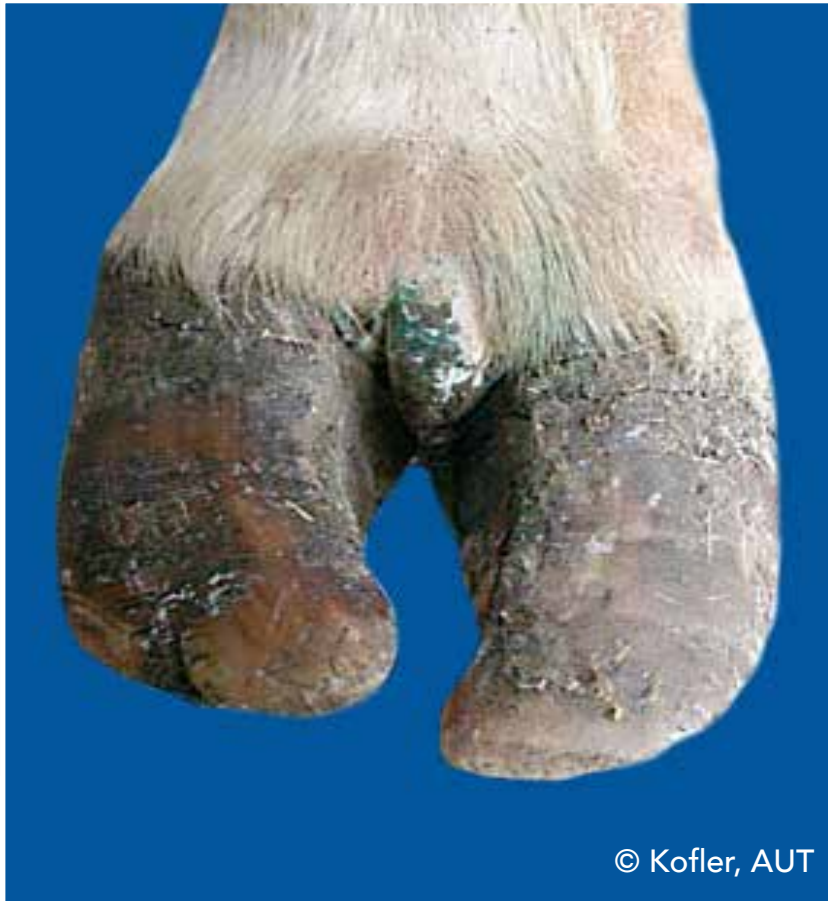Vertical (longitudinal) crack in the outer or dorsal claw wall



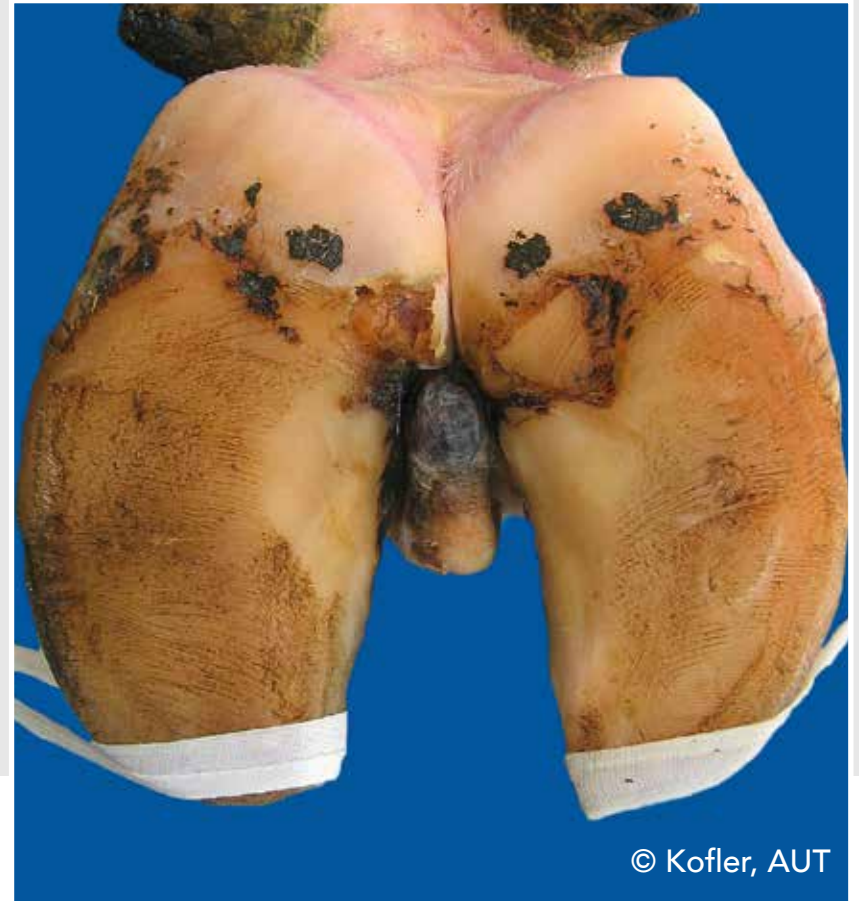
© Kofler, AUT

# Interdigital hyperplasia (IH)

Interdigital growth of fibrous tissue



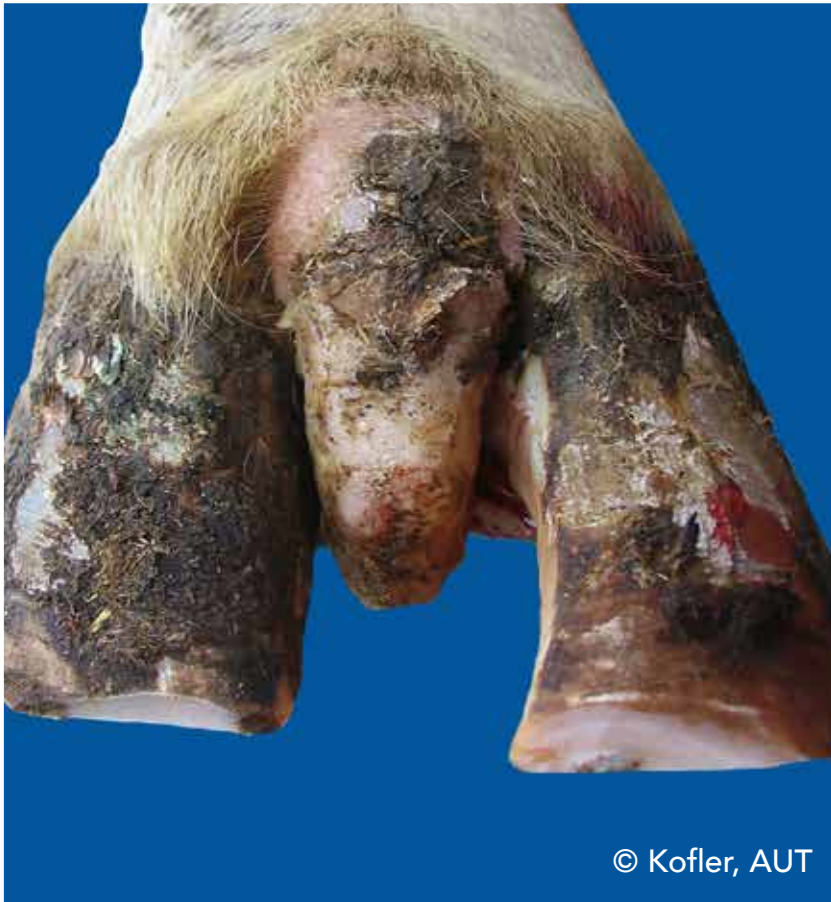© Kofler, AUT



© Kofler, AUT

# Interdigital hyperplasia (IH)

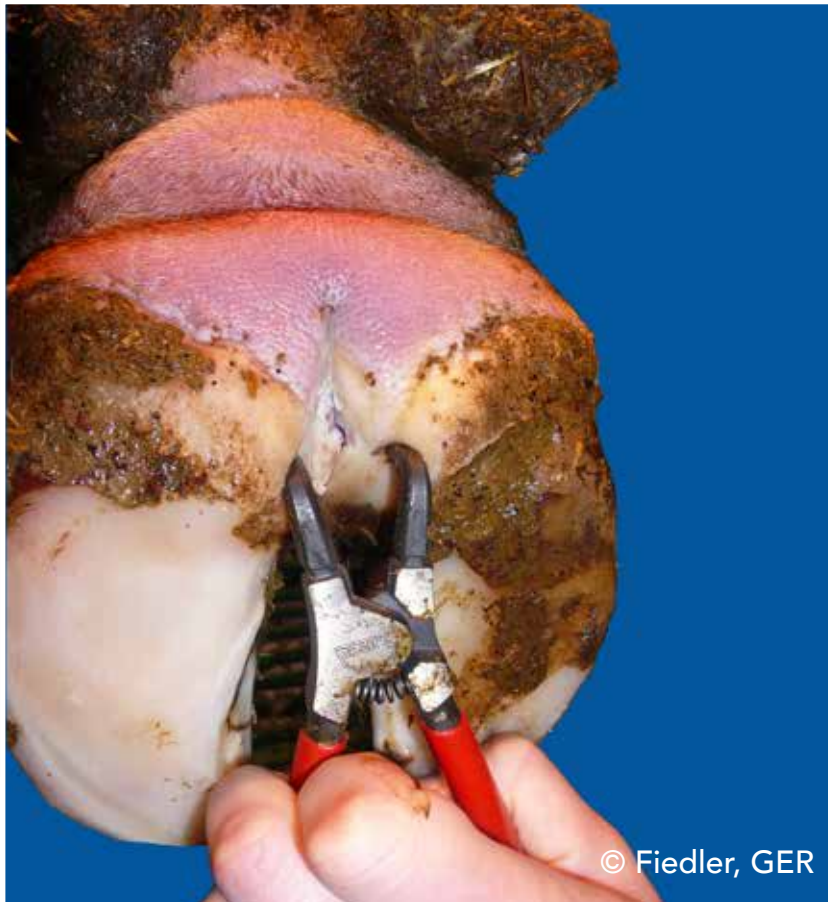Interdigital growth of fibrous tissue



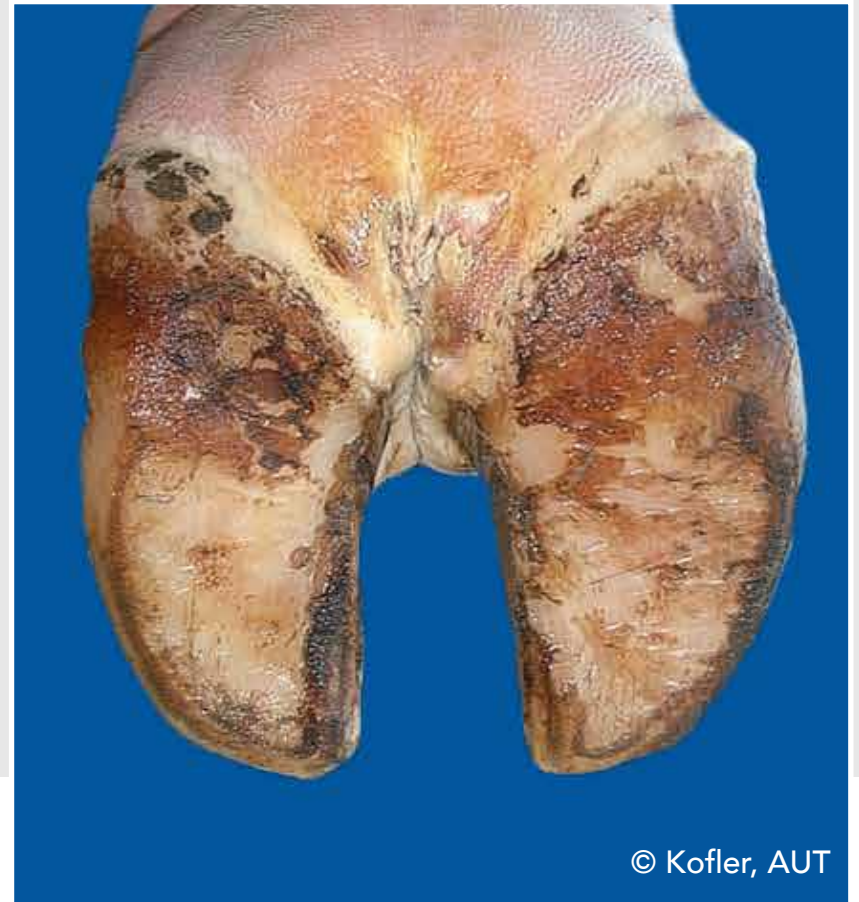
© Kofler, AUT

# Interdigital phlegmon (IP)

Symmetric painful swelling of the foot commonly accompanied with odorous smell with sudden onset of lameness



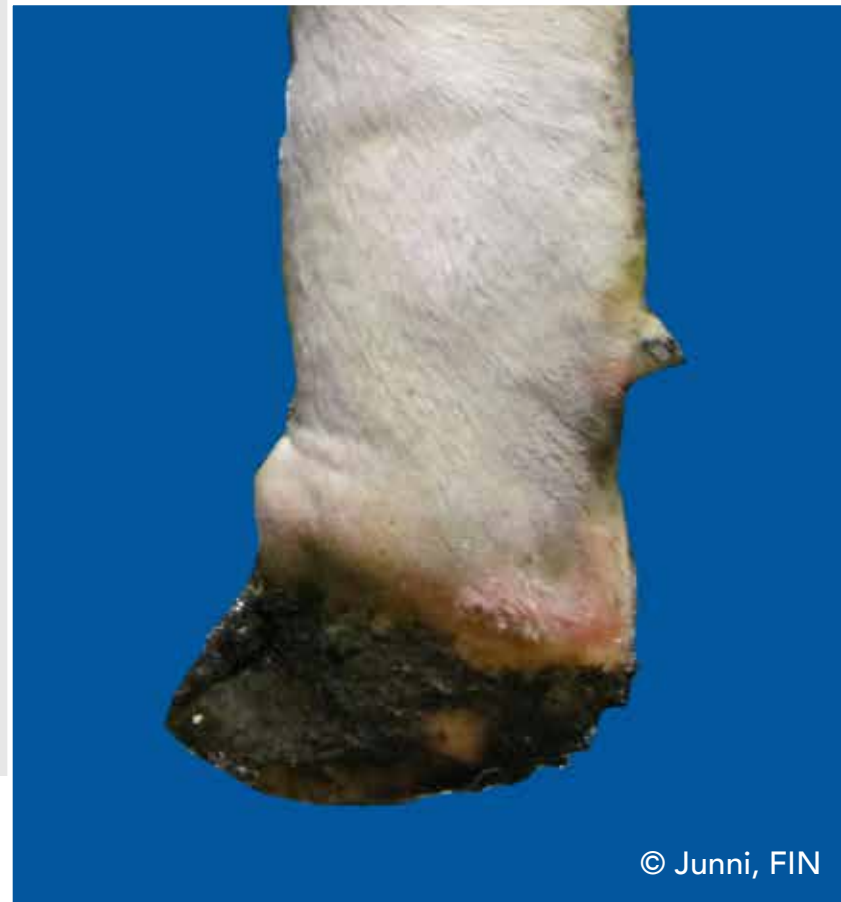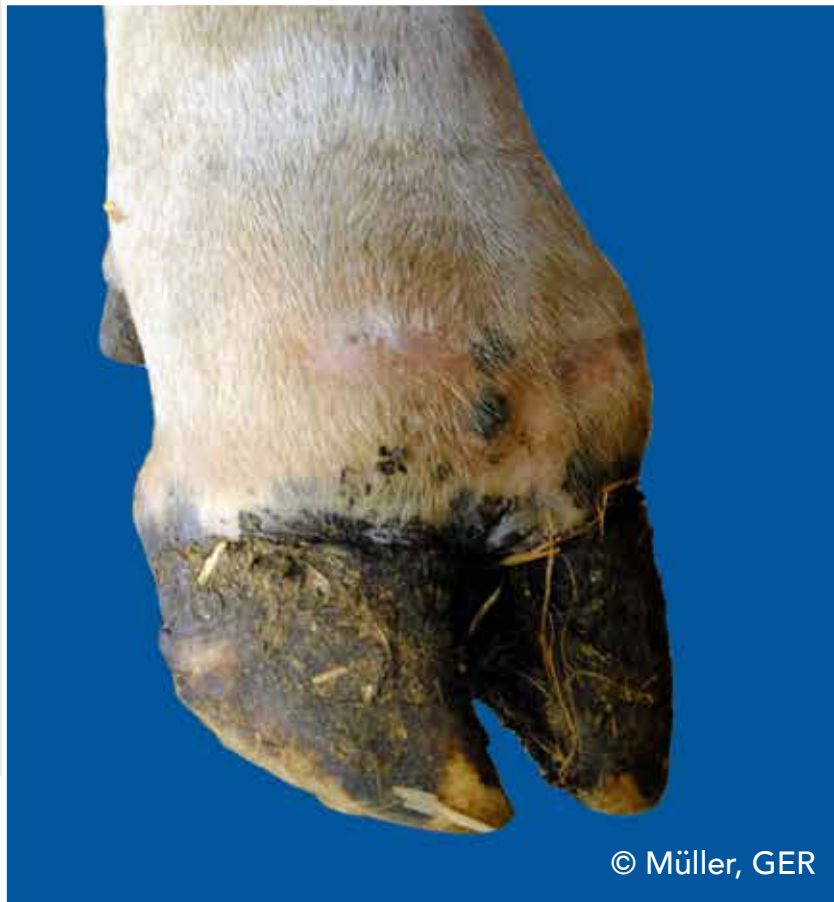© Fiedler, GER



© Kofler, AUT

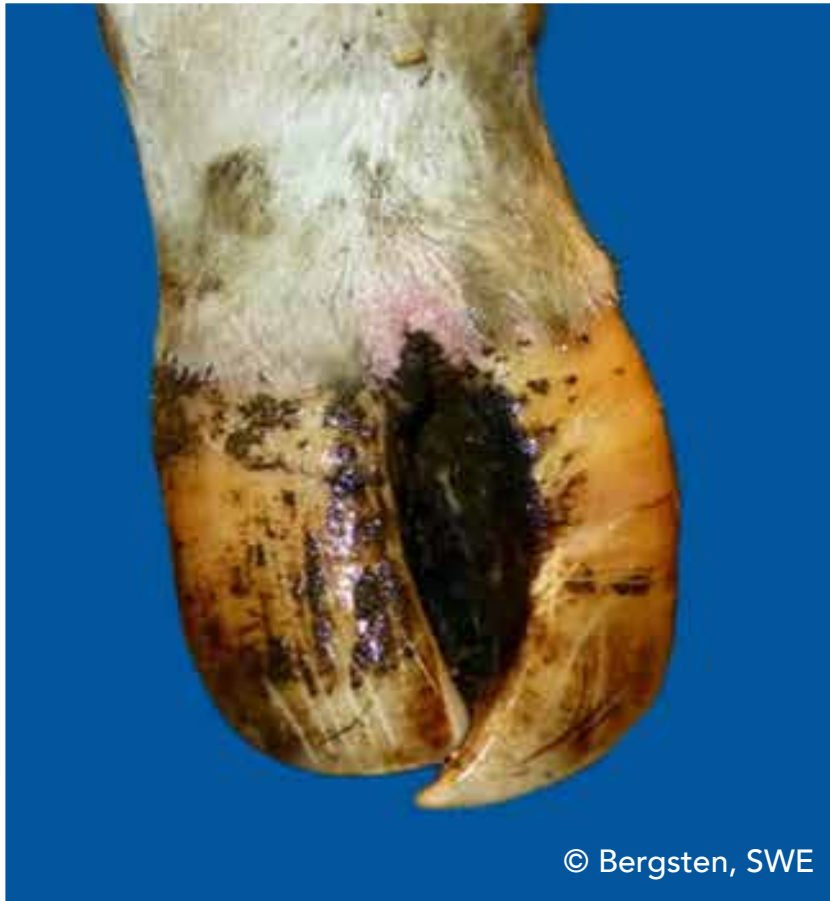# Interdigital phlegmon (IP)

Symmetric painful swelling of the foot commonly accompanied with odorous smell with sudden onset of lameness



# Scissor claws (SC)

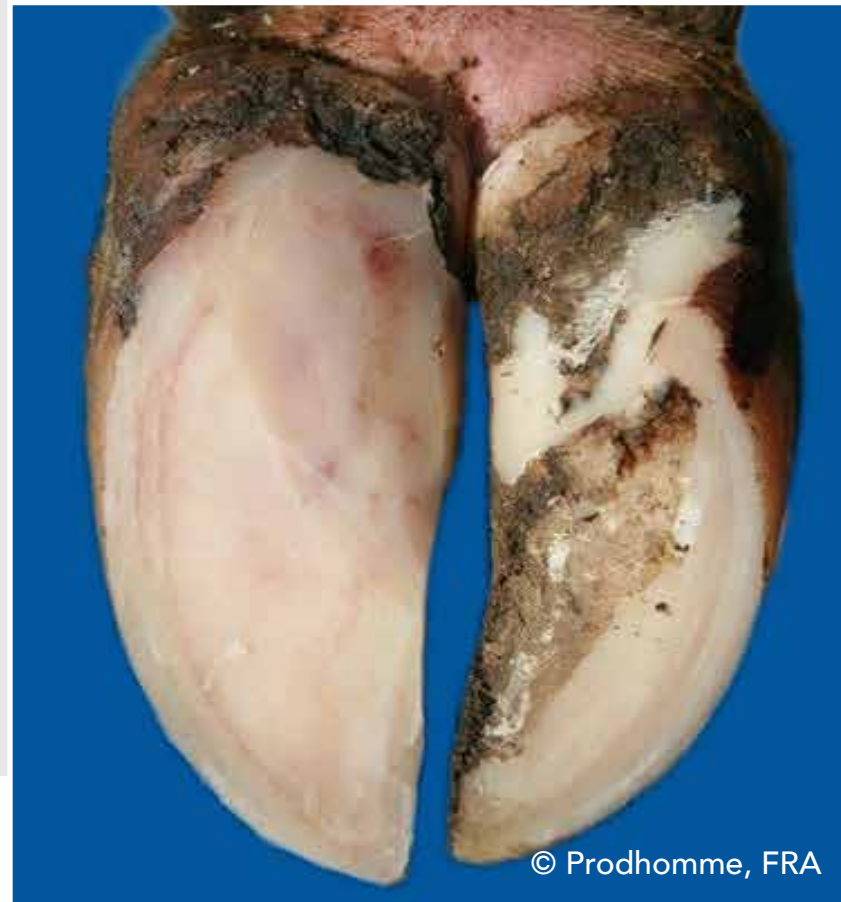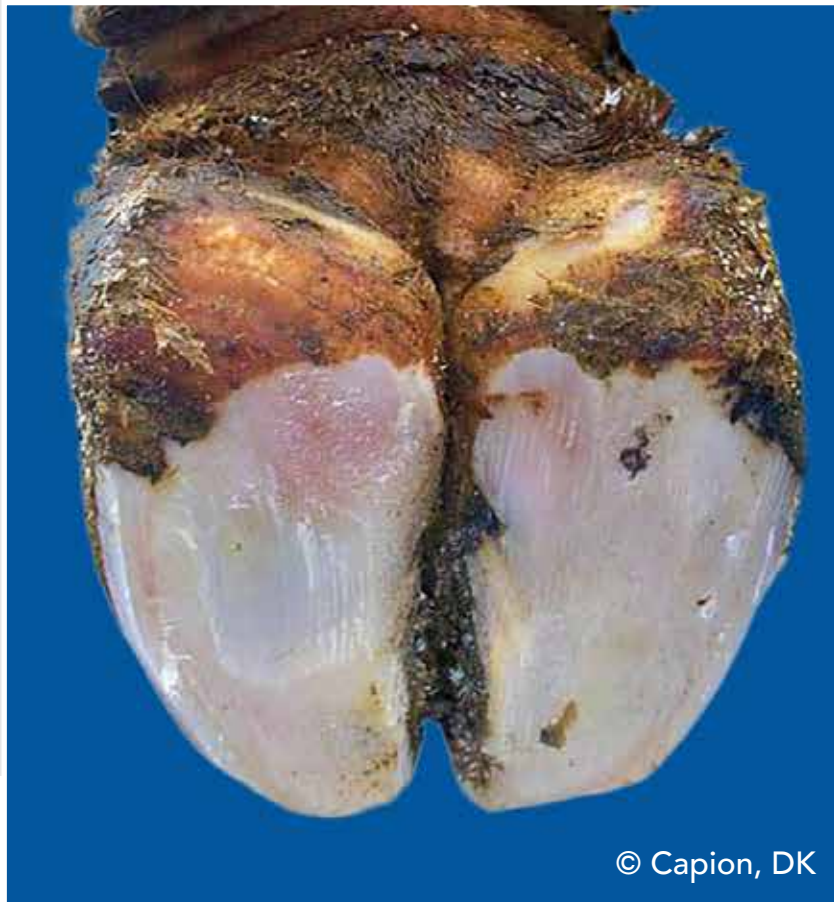
Tip of toes crossing each other



© Bergsten, SWE

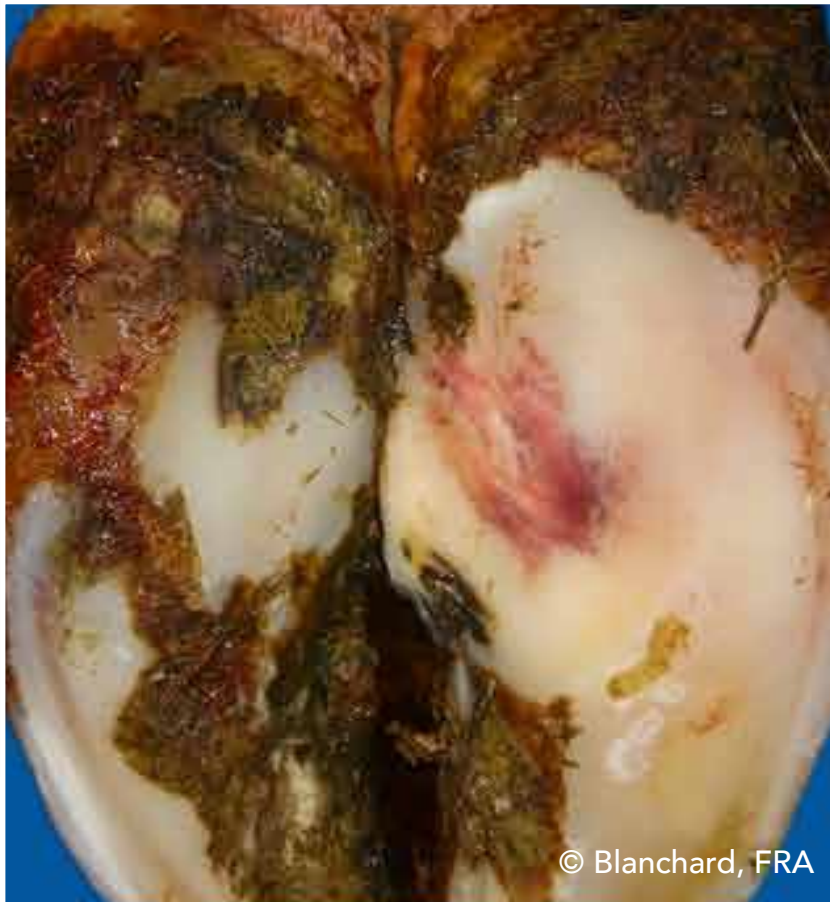# Sole hemorrhage diffused (SHD)

Diffused light red to yellowish discoloration

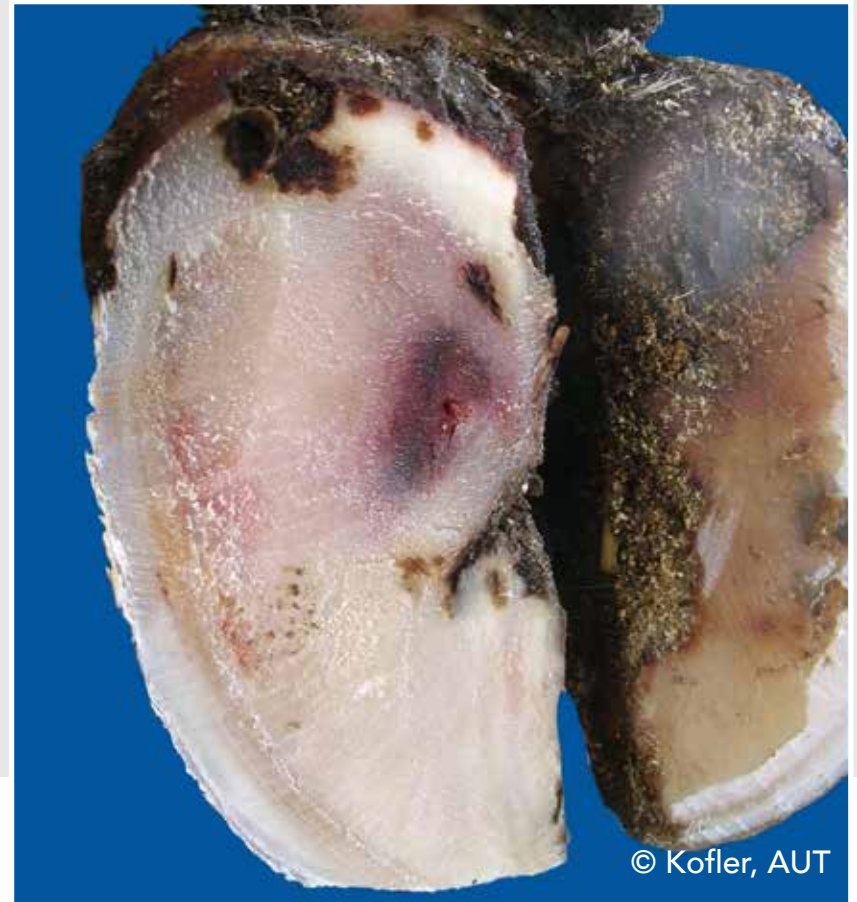

# Sole hemorrhage circumscribed (SHC)

Clear differentiation between discolored and normal colored horn



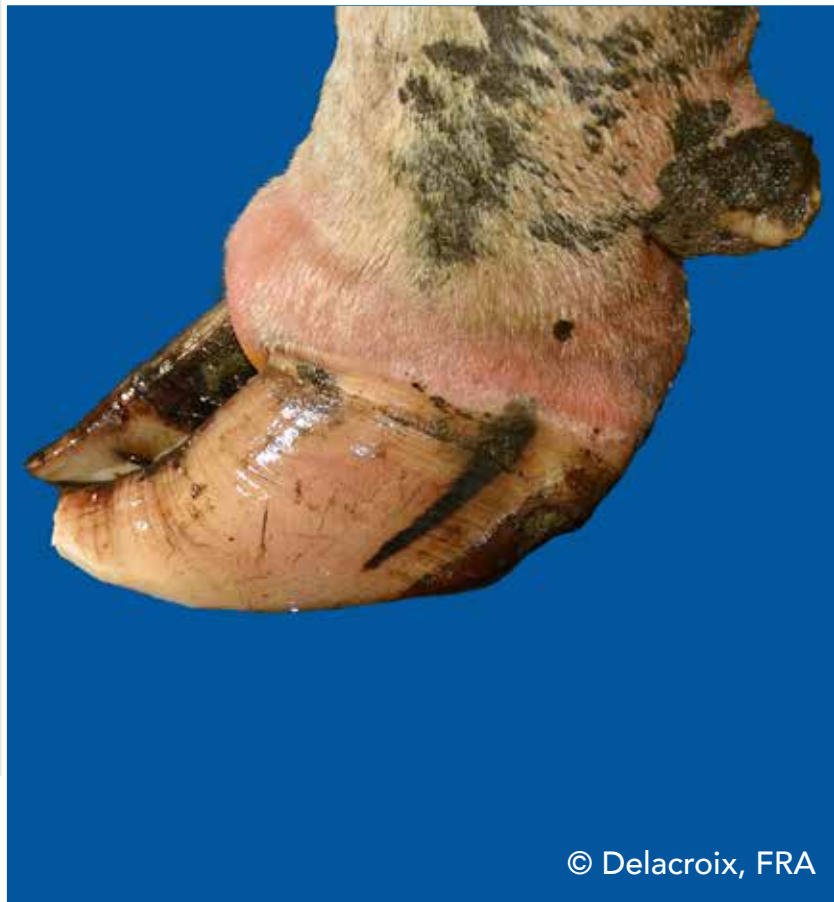© Blanchard, FRA



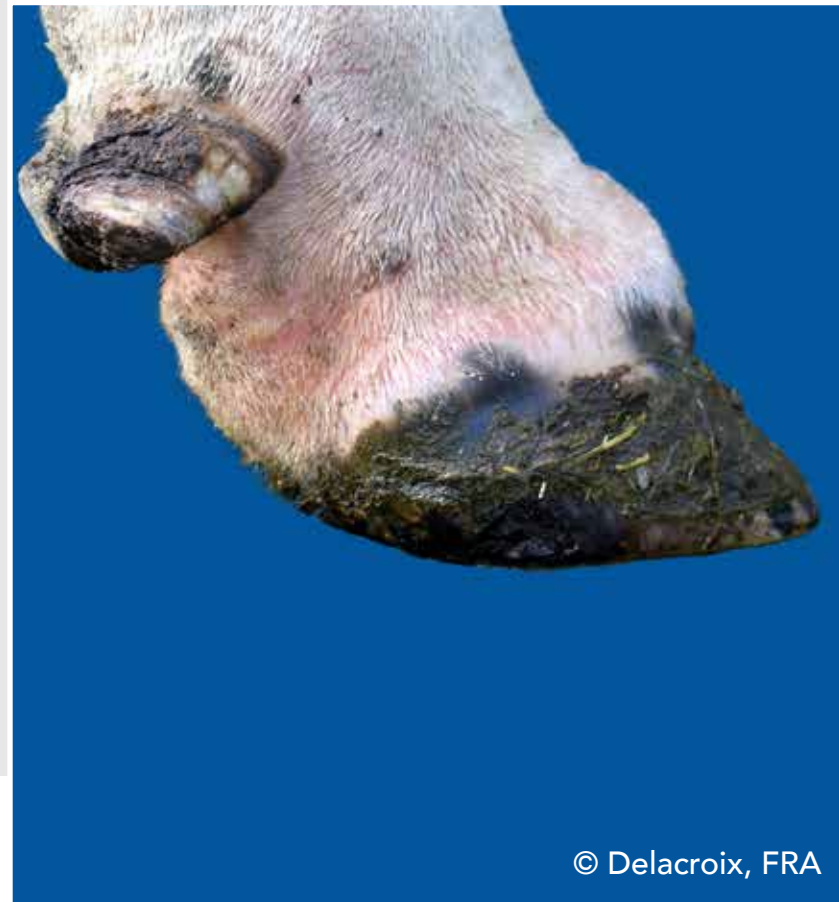
© Kofler, AUT

# Swelling of coronet and/or bulb (SW)

Uni- or bilateral swelling of tissue above horn capsule, which may be caused by different conditions



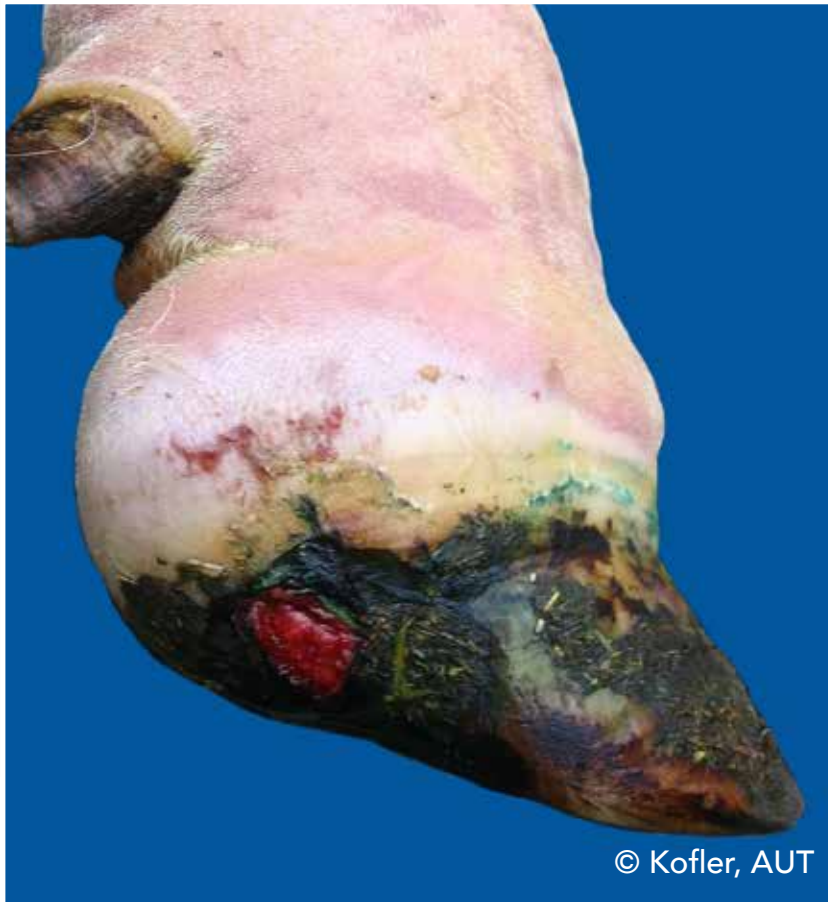© Delacroix, FRA



© Delacroix, FRA

# Swelling of coronet and/or bulb (SW)


Uni- or bilateral swelling of tissue above horn capsule, which may be caused by different conditions



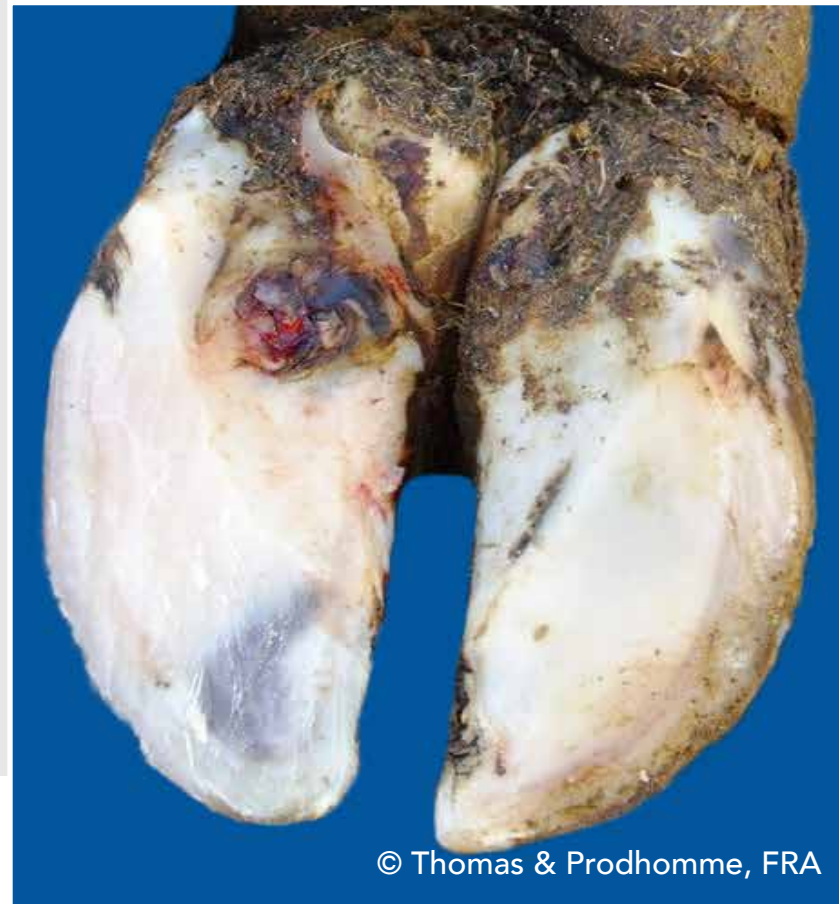© Kofler, AUT

# Sole ulcer (SU)

Penetration through the sole horn exposing fresh or necrotic corium



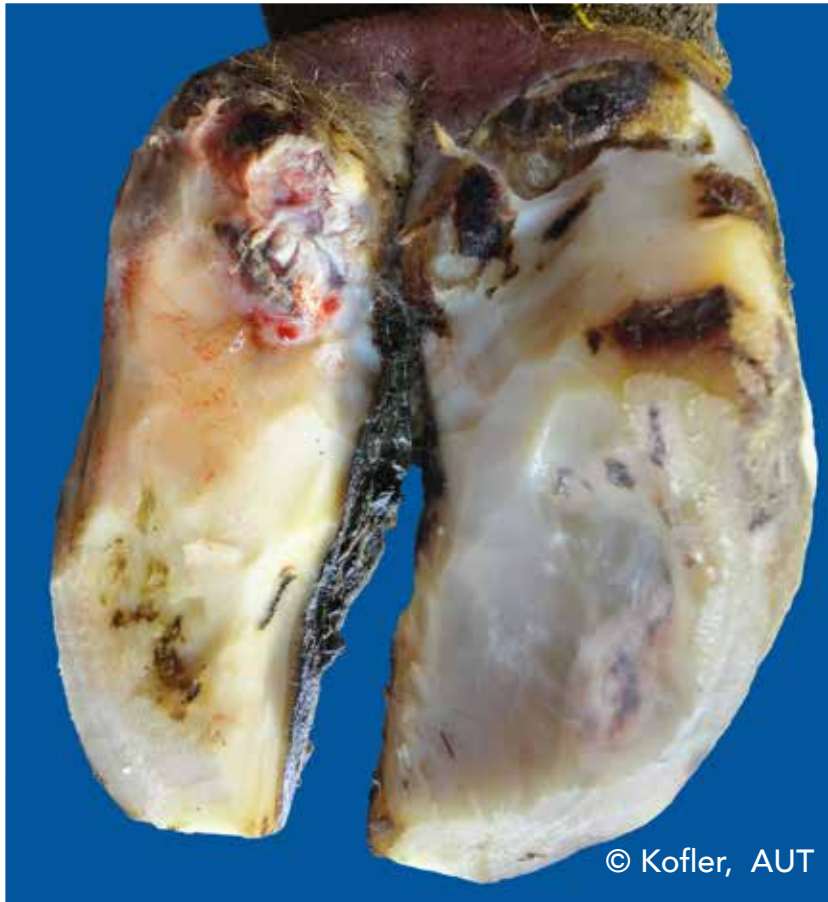© Delacroix, FRA



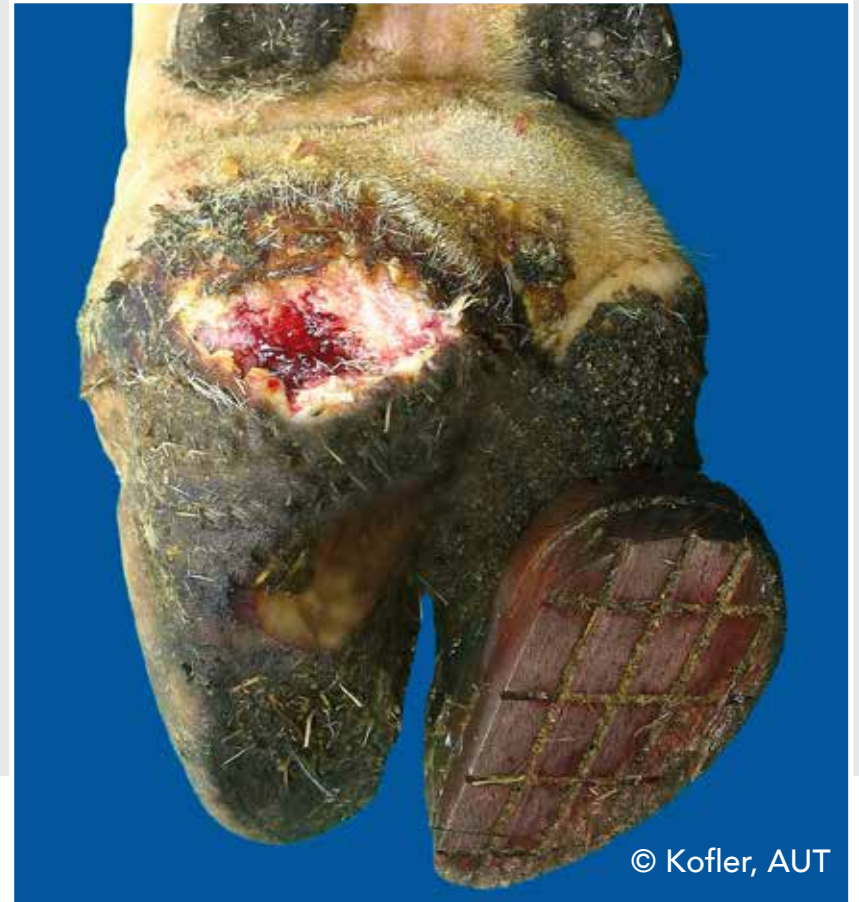© Thomas & Prodhomme, FRA

# Bulb ulcer (BU)

Ulcer located at the bulb



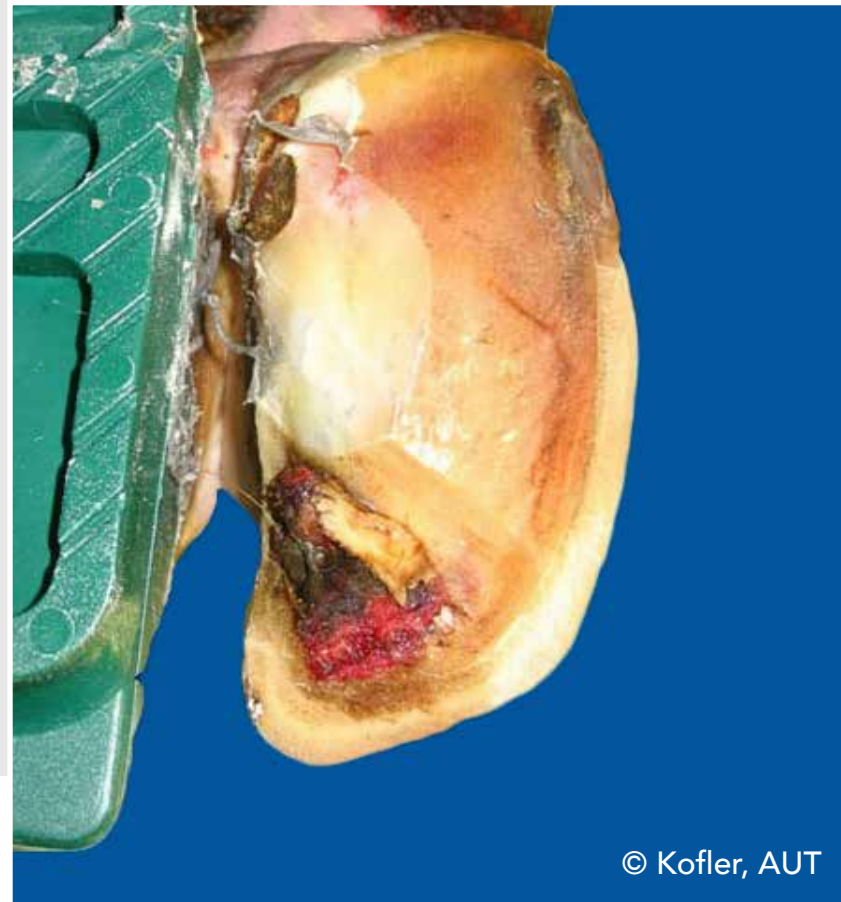
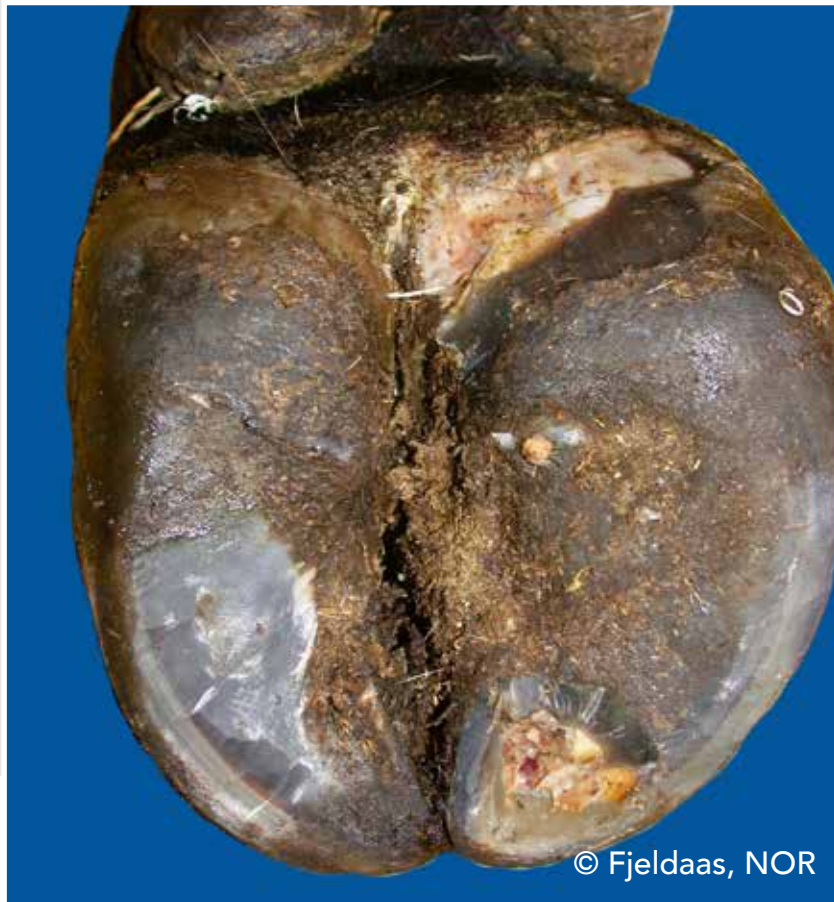© Kofler, AUT



© Kofler, AUT

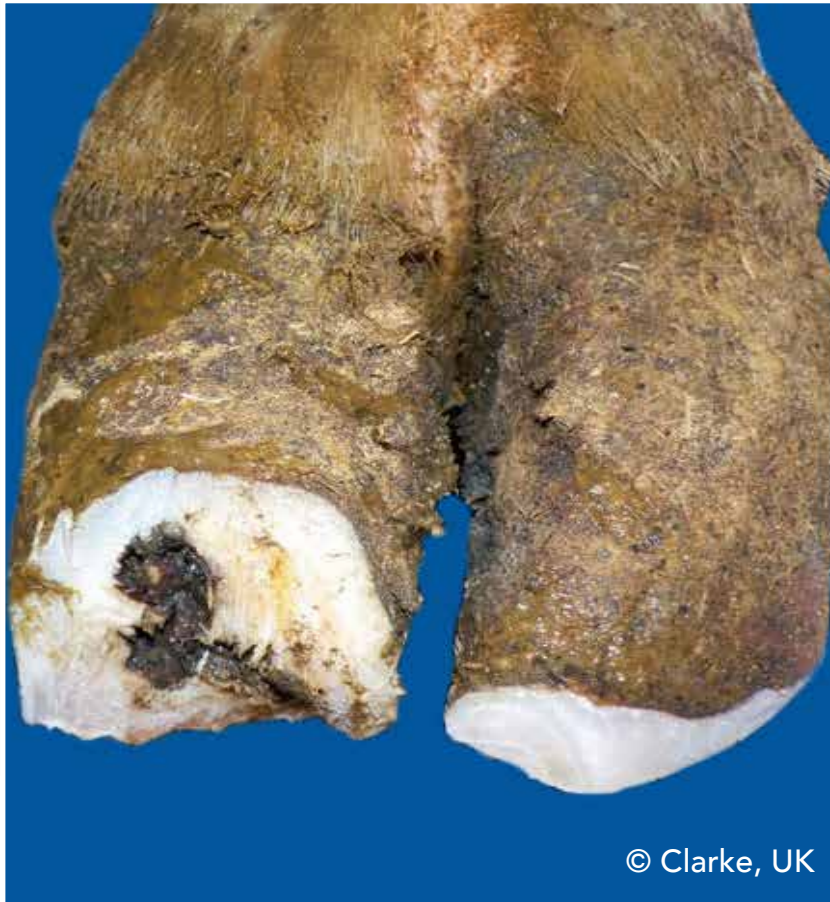# Toe ulcer (TU)

Ulcer located at the toe

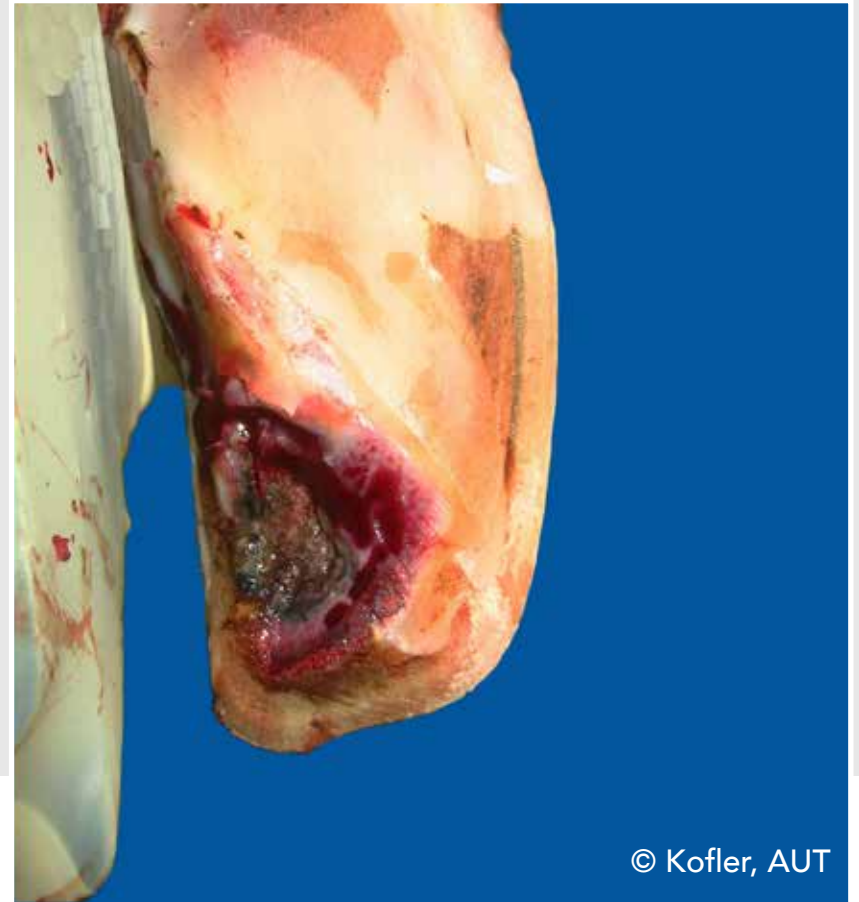

# Toe necrosis (TN)

Necrosis of the tip of the toe with involvement of bone tissue



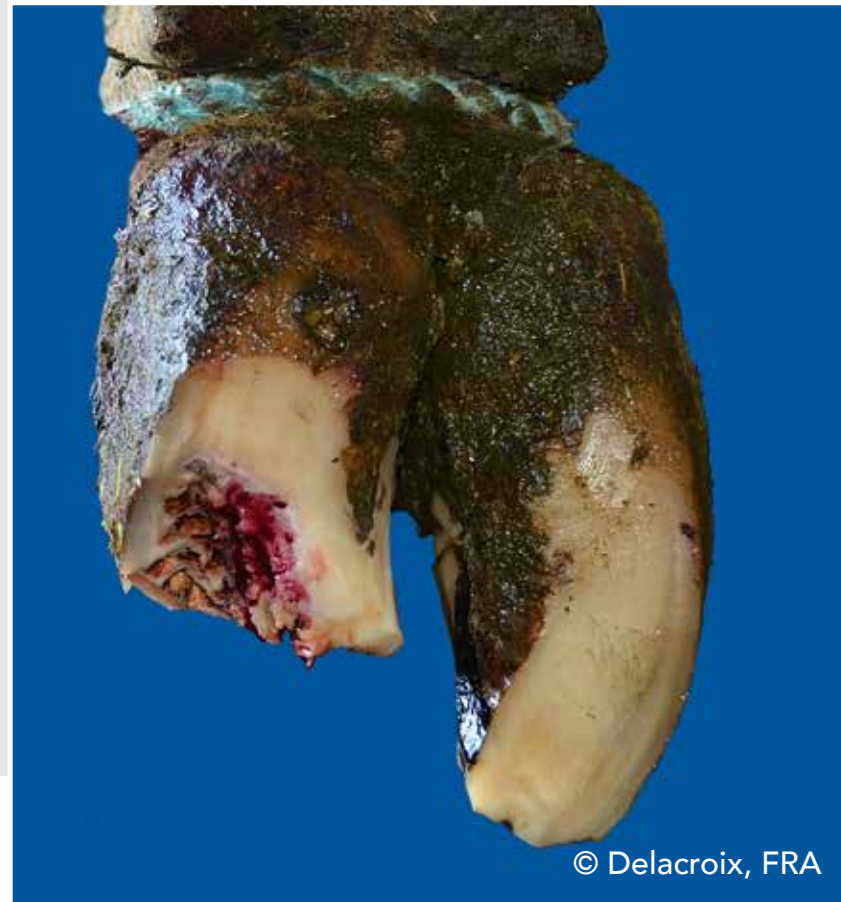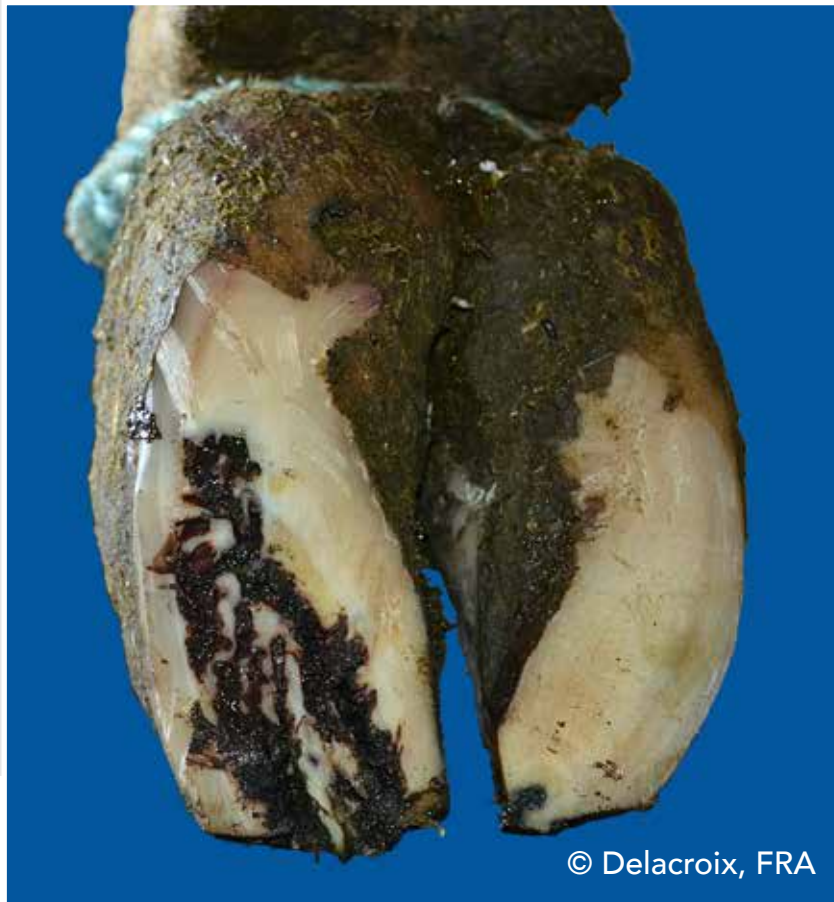© Clarke, UK



© Kofler, AUT

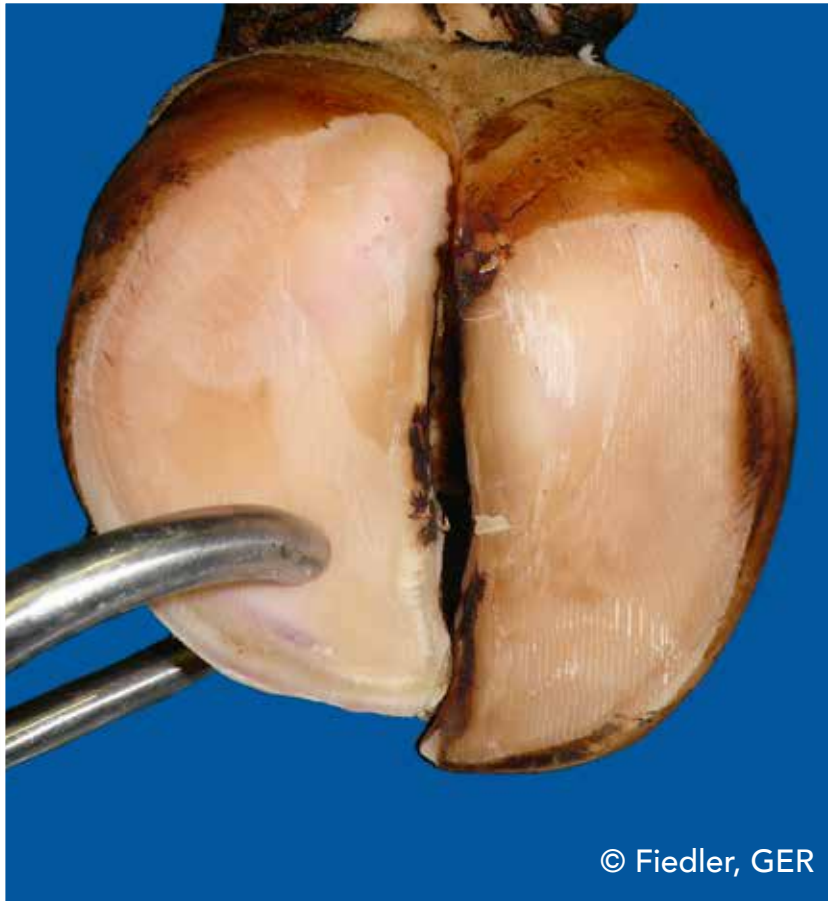
# Toe necrosis (TN)

Necrosis of the tip of the toe with involvement of bone tissue



# Thin sole (TS)

Sole horn yields (feels spongy) when finger pressure is applied



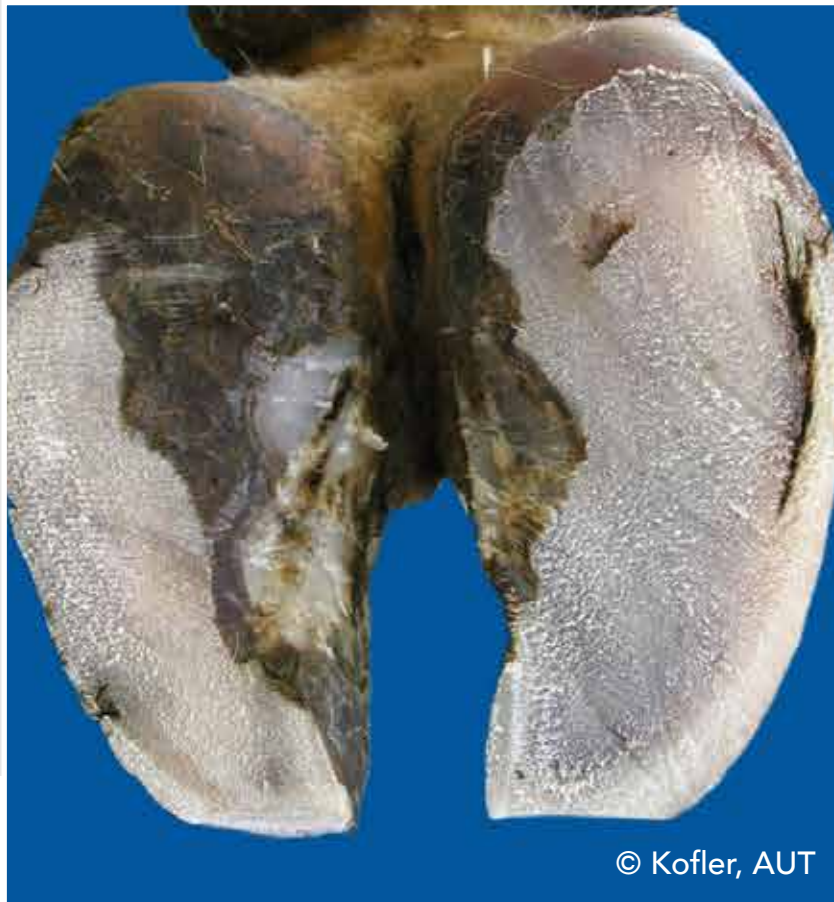© Fiedler, GER



© Fiedler, GER

# White line fissure (WLF)

Separation of the white line which remains after balancing both soles

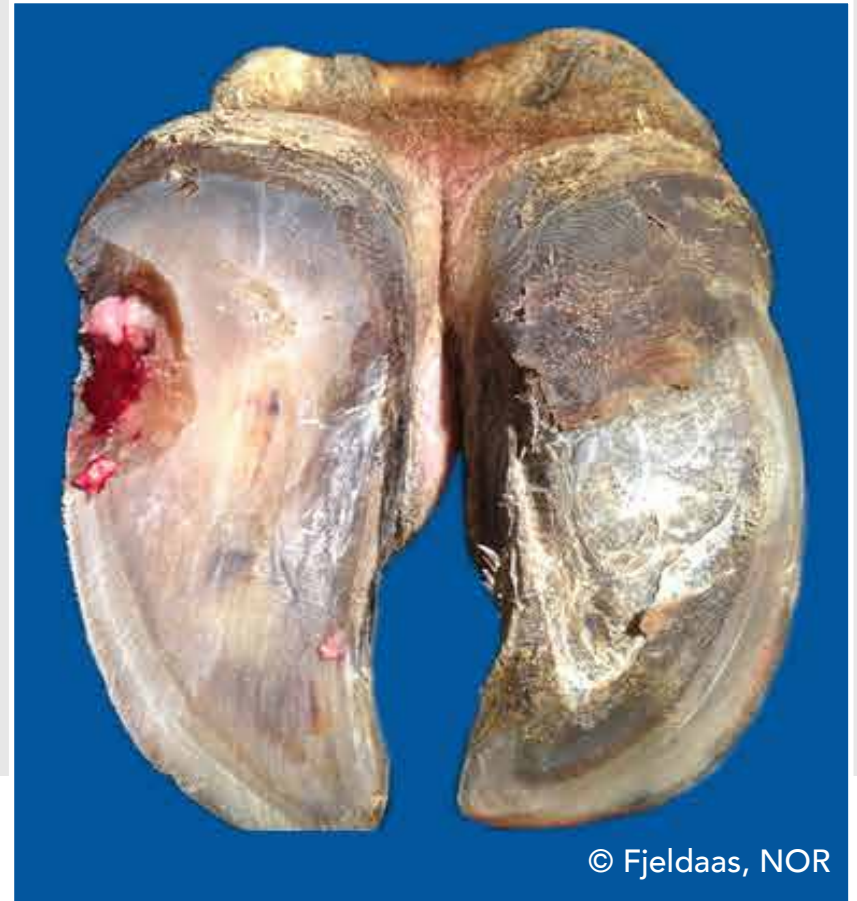


# White line abscess (WLA)

Necro-purulent inflammation of the corium



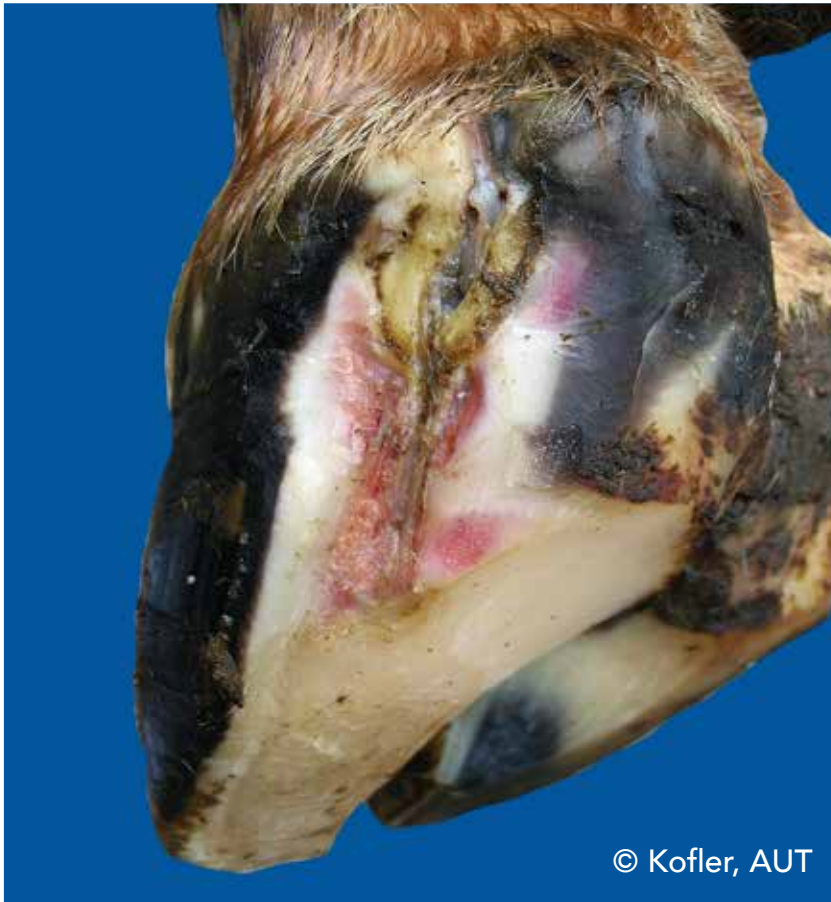© Kofler, AUT



© Fjeldaas, NOR

# White line abscess (WLA)

Necro-purulent inflammation of the corium



© Kofler, AUT

# List of Pictures

**Bergsten, Christer (SWE):** ID P18b; DS P19a; SC P30a;

**Blanchard, Joël (FRA):** SHC P32a;

**Capion, Nynne (DK):** AC P12b; SHD P31a;

**Christen, Anne-Marie (CAN):** DD P16a;

**Clarke, Jonathan (UK):** HHE P21b; TN P38a;

**Daniel, Victor (CAN):** Trimming P8;

**Delacroix, Marc (FRA):** SW P33a,b; SU P35a; TN P39a,b;

**Greenough, Paul (CAN):** HFH P24a,b;

**Hausegger, Otto (AUT):** Cover picture;

**Fiedler, Andrea (GER):** Trimming P45; AC P12a; CD P13a; DD P17a; IP P28a; TS P40a,b;

**Fjeldaas, Terje (NOR):** DS P20a; TU P37a; WLA P42b;

**Junni, Reijo (FIN):** IP P29b;

**Knappe-Poindecker, Maren (NOR):** ID P18a;

**Kofler, Johann (AUT):** CC P14a,b; DD P15b; DS P19b; HHE P22b; HFV P25a; IH P26a,b; IH P27a; IP P28b; SHC P32b; SW P34a; BU P36a,b; TU P37b; TN P38b; WLF P41a; WLA P42a; WLA P43a;



# List of Pictures

**Malmo, Jakob (AUS):** HFA P23a,b;

**Müller, Kerstin (GER):** DD P15a; HHE P21a; HHE P22a; IP P29a;

**Nielsen, Pia (DK):** Trimming P5; WLF P41b;

**Pesenhofer, Robert (AUT):** Trimming P3;

**Prodhomme, Jean (FRA):** SHD P31b; SU P35b;

**Thomas, Gilles (FRA):** CD P13b; DD P16b; SU P35b;



© Fiedler, GER



